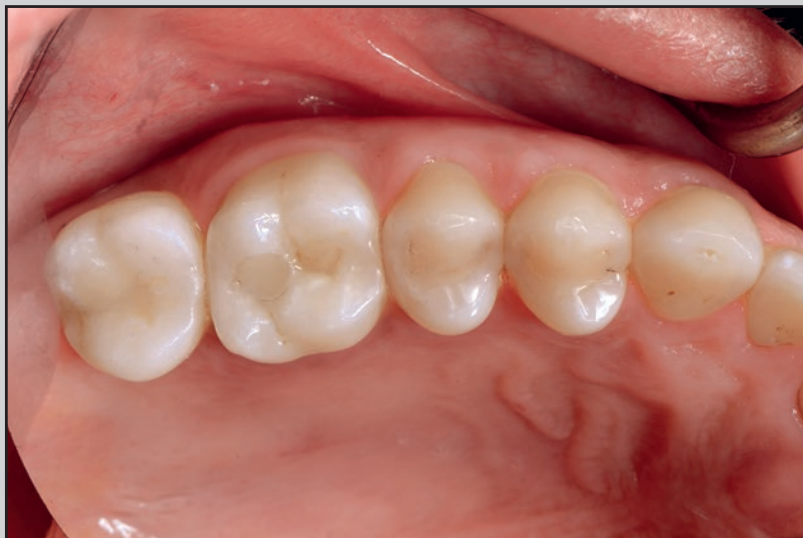
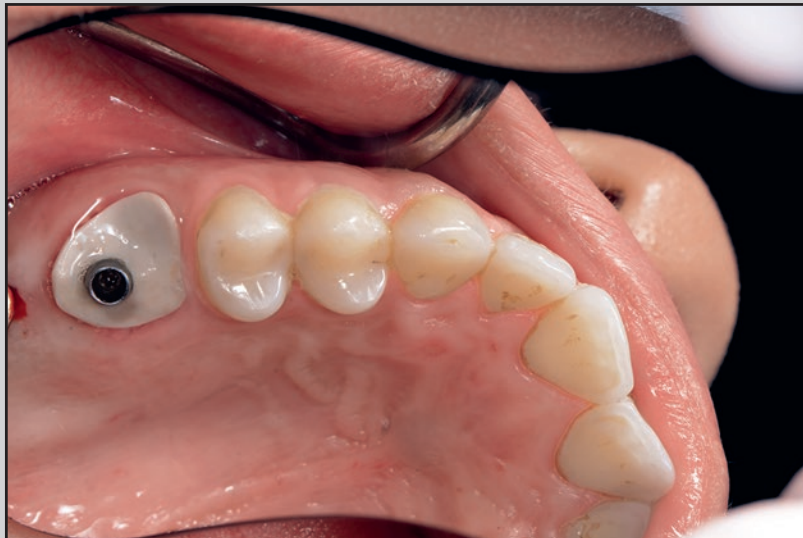
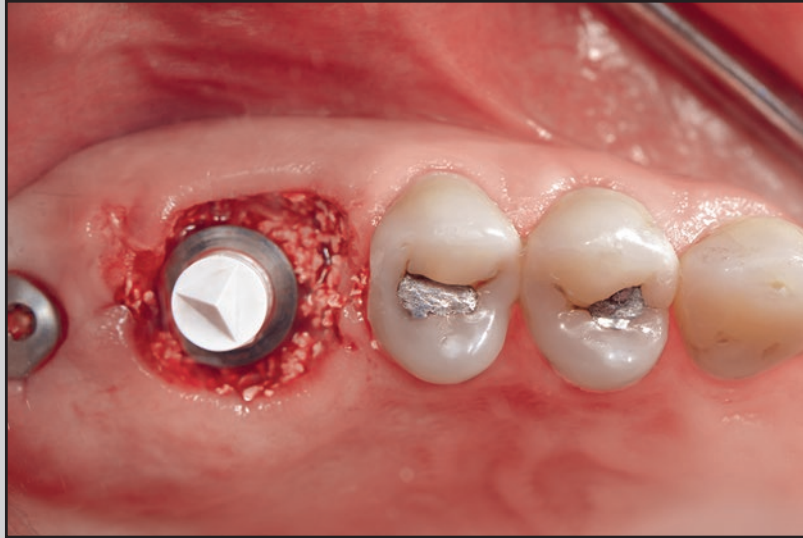Sealing Socket Abutments (SSAs) in Molar Immediate Implants with a Digitalized CAD/CAM Protocol: Soft Tissue Contour Changes and Radiographic Outcomes After 2 Years



Gary Finelle, DDS¹
 Antoine Popelut, DDS²
 Bryan Knafo, DDS³
 Ignacio Sanz Martín, PhD, DDS⁴

Immediate implant placement in molar sites has the potential to improve the patient experience by reducing the number of appointments and the overall treatment time. However, primary closure remains a technical challenge. The present prospective case series evaluated the soft tissue contours and the radiographic bone levels of 17 patients who received immediate implants in molar sites and a digitally customized CAD/CAM sealing socket abutment. At the 2-year follow-up, the mean buccal tissue contours at the most coronal portion were reduced horizontally by an average of 1 mm at 1, 2, 3, and 4 mm below the gingival margin. A mean 0.53-mm apical migration of the gingival margin was seen, and the mean interproximal bone level at the 2-year follow-up was 0.89 mm. The use of CAD/CAM-generated customized healing abutments in immediate molar sites yielded minimal hard and soft tissue changes at the 2-year follow-up. Int J Periodontics Restorative Dent 2021;41:235–244. doi: 10.11607/prd.4579

Implant dentistry has evolved toward patient-centered outcomes over recent decades in order to evaluate patients' acceptance of and satisfaction with the treatments.^{1,2} In this context, minimally invasive approaches, reduced number of interventions, shorter healing times, and preserving soft and hard tissues have gained much relevance for clinicians and researchers.

Immediate placement and provisionalization of implants placed in single anterior teeth have demonstrated positive outcomes in terms of implant survival and success, having the advantage of providing the patient with a temporary restoration at surgery and reducing the treatment time.^{3,4} Moreover, the utilization of immediate provisional restorations has been proven to maintain and stabilize the soft tissue profile.⁵ Nonetheless, immediate loading has reported a higher incidence of implant failures, as the implants are subject to masticatory forces that can result in micromotion and eventually implant failure.⁶

Although immediate implants placed in molar sites demonstrate high survival rates,⁷ immediate loading protocols are rarely utilized in posterior sites given the risks of loading the implants at surgery, and this cautiousness is even more appropriate when considering immediate loading on immediately placed

¹Private Practice, Paris, France; Visiting Faculty, Harvard School of Dental Medicine, Boston, Massachusetts, USA.

²Department of Periodontology, Pellegrin Hospital, Bordeaux, France; Private Practice, Odontia, Bordeaux, France.

³Postgraduate Resident, Hôpital Charles-Foix, Paris, France.

⁴Private Practice, Lausanne, Switzerland; Visiting Faculty, Universidad Complutense de Madrid, Madrid, Spain; Visiting Faculty, Tufts University School of Dental Medicine, Boston, Massachusetts, USA.

Correspondence to: Dr Gary Finelle, Dental 7 Paris, 59 Avenue de la Bourdonnais, 75007 Paris, France. Email: gary.finelle@dental7paris.com

Submitted August 5, 2019; accepted October 27, 2019.
 ©2021 by Quintessence Publishing Co Inc.

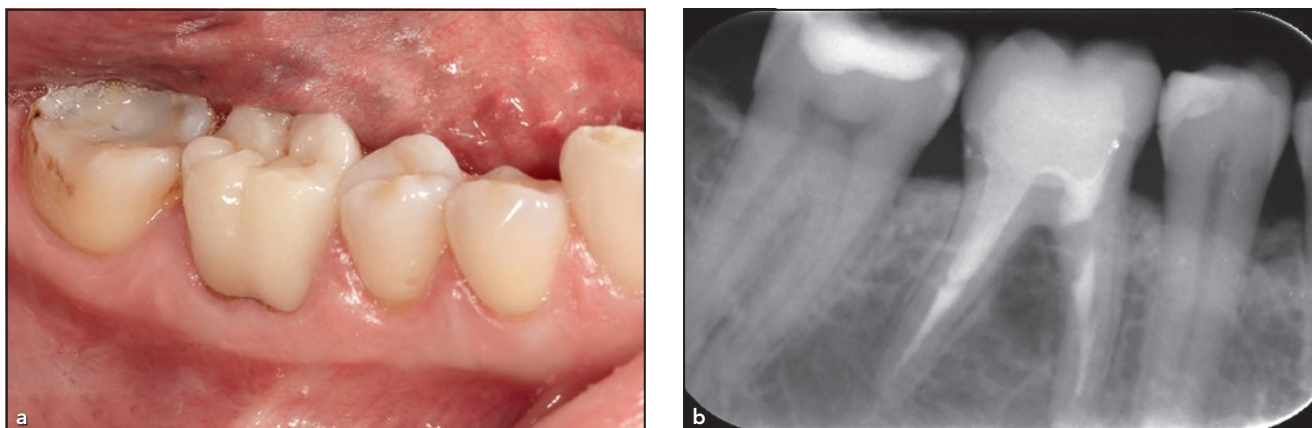


Fig 1 (a) Initial clinical situation of a fractured mandibular first molar. (b) Radiograph exhibiting signs of infection in the furcation area, confirming tooth fracture.

implants after molar extraction. If no provisional restoration is inserted to avoid the risks of implant failure after placing immediate implants in molar sites, clinicians are therefore forced to either elevate a flap and perform releasing incisions to attain soft tissue closure, augmenting the morbidity, or to leave a substantial part of the biomaterial or native bone exposed to the oral environment.

A customized, CAD/CAM-fabricated sealing socket abutment (SSA), which is used to mechanically close the molar extraction site and support the soft tissue, was recently introduced as an alternative for these particular situations.⁸ The concept is to create a customized healing abutment molding the transgingival area of the extraction socket. This SSA, which was previously described in the literature,⁹ is generated chairside using CAD/CAM at the time of the intervention. The clinical outcomes of this protocol demonstrated uneventful post-operative recovery and high implant survival in 29 patients.⁹

In spite of the positive outcomes described, there is no information to date on the results of the SSA protocol with regard to radiographic marginal bone levels and soft tissue contours. Therefore, the objective of this investigation was to assess the soft and hard tissue stability of implants placed in molar sites that received an SSA.

Materials and Methods

Study Design

The study was designed as a case series with a 2-year follow-up. Consecutive patients attending two dental offices and fulfilling the inclusion criteria were entered in the study. The outcomes of this intervention on the peri-implant buccal soft and hard tissues were evaluated by analyzing the radiographic marginal bone levels and by measuring the linear changes in tissue contours obtained from the superimposition of the baseline and

2-year follow-up stereolithography (STL) files.

Study Population

Patients aged 18 years or older who had one maxillary or mandibular molar needing extraction (Fig 1) were included in the study. Further, only patients with an intact buccal plate at the time of extraction were included. Also, an adequate bone quantity in the septum and apical regions (assessed by CBCT) was required for the proper stabilization of the immediate implants and manufacturing of the SSA. All patients read and signed the written informed consent before surgery.

Exclusion criteria routinely applied for clinical trials were utilized: uncontrolled metabolic disorders, conditions that may affect hard or soft tissue, alcoholism or drug abuse, history of immunodeficiency syndromes, smokers consuming > 10 cigarettes per day, local inflammation (including untreated peri-

odontitis), mucosal diseases such as erosive lichen planus, a history of local radiotherapy, severe bruxism, and persistent intraoral infection. Finally, the exclusion criterion at surgery was the lack of primary stability at implant placement.

Study Procedures

Surgical procedure and clinical measurements

Surgery was performed under local anesthesia. Molar extractions were performed with the aid of root sectioning in the least traumatic way to minimize tissue damage. After extraction, the alveolar sockets were generously irrigated with sterile saline solution and cleaned with curettes to remove any granulation tissue. Dental implants were immediately inserted flaplessly, aimed toward the septum of the socket, with the shoulder placed approximately 1 mm below the buccal bone plate and approximately 4 mm below the gingival margin (GM; Fig 2).

Materials

Seventeen Straumann implants (wide neck, regular neck, Standard Plus, or Bone Level Tapered) were placed following the manufacturer's recommendations and in accordance with the ideal, prosthetically driven location, as planned during the preoperative virtual planning. The insertion torque was recorded during placement and reached a minimum of 15 N/cm. A xenograft bone substitute (Cerabone, granules, Botiss Biomaterials) was gently packed to fill the alveolar socket

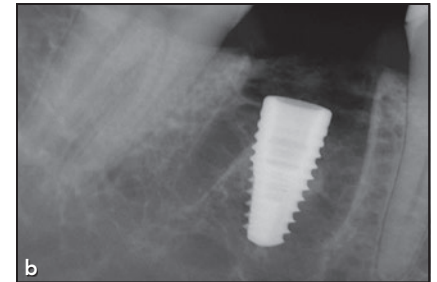
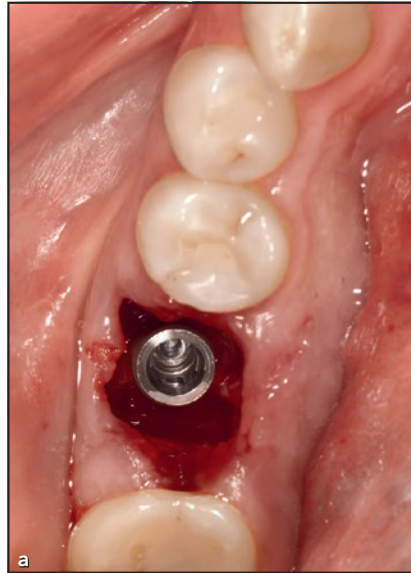


Fig 2 (a) Occlusal view of the placed implant. (b) Postoperative radiograph to verify adequate implant placement.

surrounding the implant. To obtain socket closure at the time of extraction, a detailed^{8,9} digitally generated protocol was established to allow for an immediate customized CAD/CAM abutment to be placed at the time of surgery. In brief, a scanbody (CEREC, Dentsply Sirona) was connected onto the platform of the implant, and a digital impression was performed by means of an intraoral scanner (CEREC Omnicam, Dentsply Sirona). After acquisition, the SSA was designed on the prosthetic software, and the digital file was exported to an in-office milling system (CEREC MC XL, Dentsply Sirona; Figs 3a and 3b) for chairside fabrication of the SSA abutment (Telio CAD A16, Ivoclar Vivadent; Figs 3c to 3e). The SSA was then cemented to an intermediate titanium abutment (Variobase, Straumann) and screwed into the implant (Fig 4).

Final prosthesis placement

After 3 to 4 months, the SSA was removed, the healing and appearance of the peri-implant tissues were assessed, and osseointegration was validated (Fig 5). The abutment was removed, and a final digital impression was performed. A digital impression using a proper implant scanbody (Straumann Mono Scanbody) was taken for the implant-supported restoration. STL files of the final impression were exported to open design software (DWOS CAD, Dental Wings). The transmucosal design was guided by the morphology of the previously customized SSA. All implants placed allowed for a screw-retained designed and monolithic prosthesis (lithium disilicate or zirconia) bonded on a titanium base (Variobase, Straumann).

Follow-up

Follow-up evaluations were performed after extraction and implant

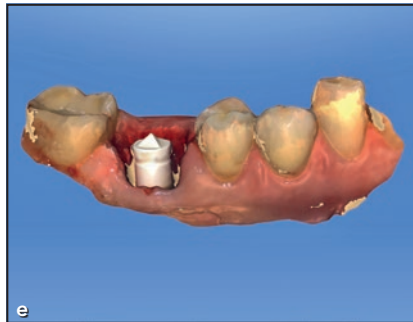
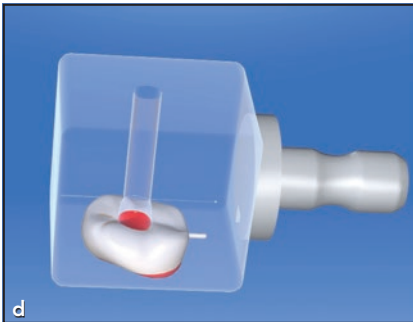
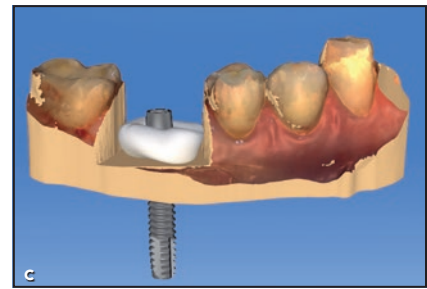
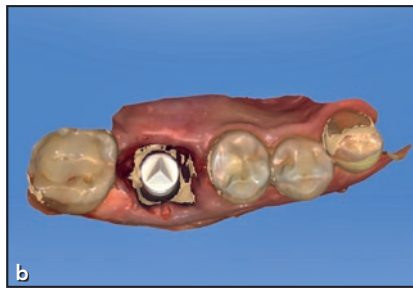
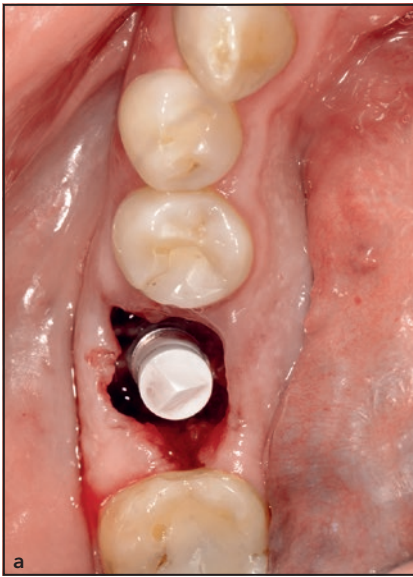


Fig 3 (a) Occlusal view at insertion of the scanbody onto the implant after extraction and implant placement. (b) Occlusal view of the digital impression utilized for SSA design and fabrication. (c) Buccal view of the digital impression utilized for SSA design and fabrication. (d) Buccal view of the SSA chairside design onto the virtual model. (e) Nesting of the SSA abutment into the virtual bloc.

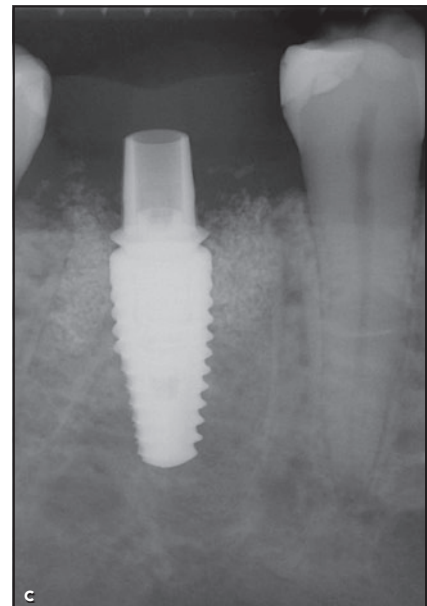
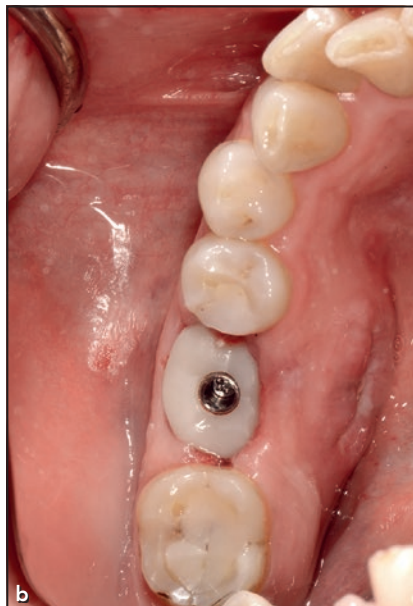
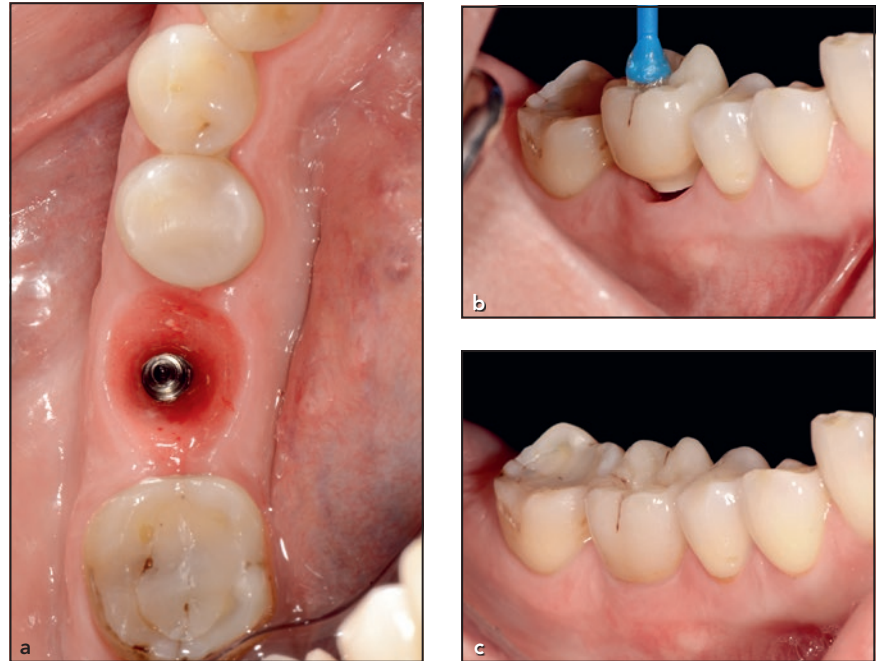


Fig 4 (a) Milled SSA attached to the polymethyl methacrylate bloc before bonding to the titanium base. (b) SSA inserted onto the implant at time of surgery. (c) Postoperative periapical radiograph.

Fig 5 (a) Occlusal view after SSA removal at the time of osseointegration at the 3-month restorative follow-up. (b) Final crown delivery at the time of insertion and (c) when fully seated.



surgery (baseline [BS]), after crown insertion, and 24 months (2Y) after crown insertion (Fig 6).

Outcome Variables

STL image acquisition and matching of data

Intraoral digital impressions were performed by means of an intraoral scanner (CEREC Omnicam) after extraction at the time of scanbody connection (BS) and 2 years after the delivery of the prosthetic restoration.

The BS and 2Y follow-up STL files were uploaded to an image analysis software (SMOP, Swissmeda). To match the STL files, three clear and visible pairs of reference points were selected in both the BS and 2Y casts, allowing the software to perform a “rough fit.” After this, additional references (no fewer

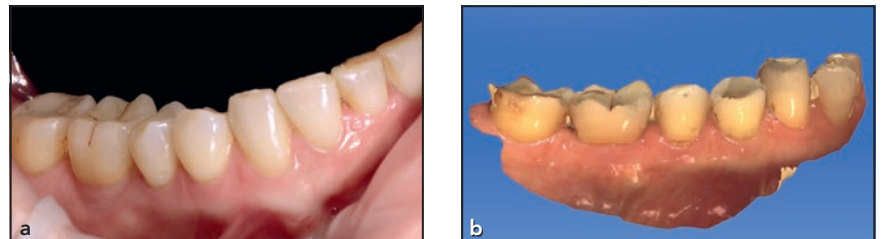


Fig 6 (a) Buccal view of the final crown and (b) an STL file of the clinical situation at the 2-year follow-up.

than 10) were selected to assist the matching and perform a “fine fit” of the surfaces. Then, using a series of mathematical algorithms to achieve a best-fit, the software automatically superimposed the models.

STL image analysis: Contour changes

The superimposed STL files allowed measuring of the changes in tissue contours from BS to 2Y using a previously reported methodology.^{10,11} At BS, linear measurements were

performed from the cross-sectional views at the middle of the scanbody: A line coinciding with the axis of the implant was drawn, and lines perpendicular to this axis were drawn at 1, 2, 3, and 4 mm below the GM (Fig 7). The horizontal dimensions of the tissue contours were then measured at these different heights at BS and 2Y (Fig 8). The mucosal recession was also assessed by measuring the distance of GM at the different time points.

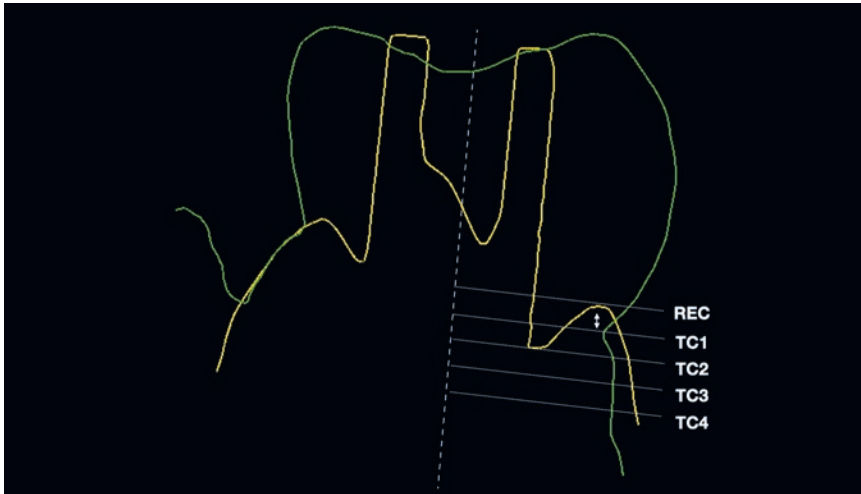


Fig 7 Outline of baseline (yellow) and 2-year follow-up (green) STLs with schematic representations of linear measurements performed in the central section. REC = recession of the gingival margin; TC1, TC2, TC3, and TC4 = tissue contours at 1, 2, 3, and 4 mm, respectively, below the gingival margin.

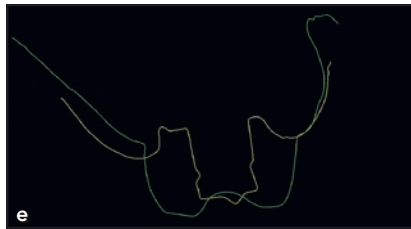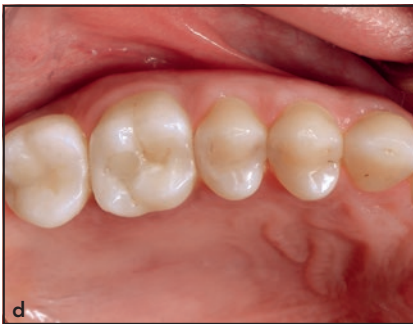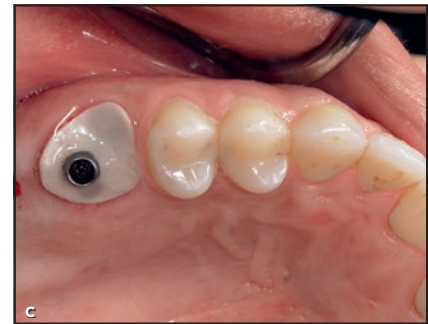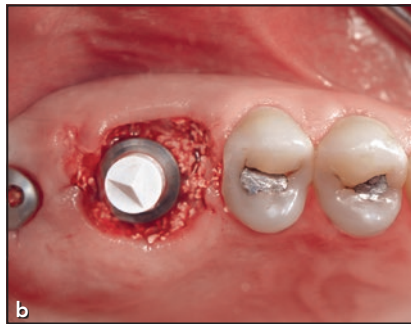


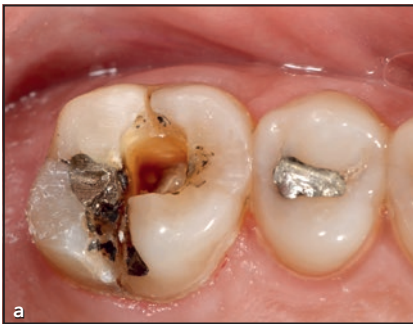Fig 8 (a) Occlusal view of the fractured and nonrestorable maxillary first molar. (b) Occlusal view at insertion of the scan-body onto the implant after extraction, implant placement, and bone preservation. (c) Occlusal view after SSA abutment insertion and (d) at the 2-year follow-up. (e) Superimposition of baseline (yellow) and 2-year follow-up (green) STL files of the soft tissue contours.

Radiographic evaluation of interproximal bone levels

The position of the interproximal bone levels 2Y after the delivery of the restorations was measured from periapical radiographs taken with a parallel technique and the use of Rinn holders. These bone levels (distance from the implant shoulder

to first bone contact [DIB]), once calibrated by the distance between two implant threads or the length of the implant, were measured at the mesial and distal aspects of each implant by means of computer image analysis software (ImageJ, National Institutes of Health).

Statistical Analysis

Descriptive statistics of continuous variables were analyzed using a statistical software program (SPSS version 20.0, IBM). Data were tested for normality by means of Shapiro-Wilk test. Repeated measures analysis of variance was used for the within-

Table 1 Contour Changes from Baseline to the 2-Year Follow-up

Distance below the GM	Contour, mm		Mean \pm SD difference, mm (%)	P
	Baseline	2 y		
1 mm	6.90 \pm 1.06	5.85 \pm 1.20	0.96 \pm 0.77 (15%)	< .001
2 mm	7.43 \pm 1.08	6.10 \pm 1.12	1.33 \pm 0.87 (17%)	< .001
3 mm	7.84 \pm 0.99	6.71 \pm 1.30	1.20 \pm 0.96 (14%)	< .001
4 mm	8.23 \pm 0.93	7.19 \pm 1.35	0.87 \pm 1.06 (12%)	.003

GM = gingival margin.

subjects comparisons of the primary outcome (linear STL measurements). Statistical significance was set at $\alpha = .05$.

Results

Seventeen patients completed the 2-year follow-up. The need for tooth extraction varied and included root fracture (9 patients), caries (2 patients), and insufficient tooth structure (6 patients). The sample consisted of 7 women and 10 men with an age range of 34 to 82 years of age (mean: 58.7 years). Patients were systemically healthy, and 6 patients were mild smokers (< 10 cigarettes/day).

Six implants were placed in the maxillary first molar position, one in the maxillary second molar position, nine in the mandibular first molar position, and one in the second maxillary molar position.

Healing was uneventful in all patients. Two patients presented mobility of the SSA, which was retightened without further complications. No infections or biologic complications were reported 8 days post-operatively, at restorative appoint-

ments, or at the 2-year follow-up appointment. At the appointment for the final impression, all implants showed clinical signs of osseointegration.

Tissue Contours and Gingival Recession

The mean gingival recession at 24 months after placement was 0.53 \pm 0.35 mm, and there was a horizontal reduction in the tissue contour dimensions, ranging between 0.3 and 1.6 mm at the different heights: 0.96 \pm 0.77 mm at 1 mm below the GM, 1.33 \pm 0.87 mm at 2 mm below, 1.20 \pm 0.96 mm at 3 mm below, and 0.87 \pm 1.06 mm at 4 mm below. The percentage of ridge reduction ranged from 12% to 17%. The change between BS and 2Y values was significant at all heights (Table 1).

Interproximal Bone Levels

At 2Y, the mean mesial DIB value was 0.79 \pm 0.51 mm, the mean distal value was 0.99 \pm 0.54 mm, and the overall mean DIB was 0.89 \pm 0.50 mm.

Discussion

This prospective case series evaluated the soft and hard tissues in the molar area after immediate implantation and the use of CAD/CAM-generated customized healing abutments. At 2Y, the mean buccal tissue contours were reduced an average of 1 mm horizontally at 1, 2, 3, and 4 mm below the GM. There was a mean apical GM migration of 0.53 mm. The mean interproximal bone level at 2Y was 0.89 mm. These minimal changes in the soft and hard tissues allowed preservation of the alveolar ridge dimensions, rendering an optimal integration of the restoration with the adjacent tissues.

The main advantage of utilizing customized healing abutments after molar implantation is the maintenance of the tissue contours by giving support to the soft tissues in the transmucosal area. This approach replicates the advantages of immediate provisionalization, which have been widely reported,^{12,13} without the possible disadvantages related to the immediate implant loading.

The proposed protocol was particularly successful in maintain-

ing the GM position, as minimal recession (0.5 mm) was encountered. The effect of provisional restoration on the stability of the GM is controversial. While Block et al¹⁴ found a significant advantage using provisional restorations for GM stability and reported that supporting the GM with a provisional restoration at the time of tooth extraction and implant placement was able to better preserve the facial GM position as opposed to the delayed implant group, other investigations have found no benefit in the use of immediate provisionalization to improve GM stability.^{15,16}

In spite of the attempts to minimize hard and soft tissue collapse through the use of the SSA and a bone substitute, significant changes occurred from BS to 2Y. The observed reduction in tissue contours may be related mostly to the reduction in the osseous ridge dimensions, which has been reported to occur even when grafting the socket with bone substitute.¹⁷

Regardless of the significance of the changes in tissue contours, the collapse was minimal, extending approximately 1 mm at the different heights below the GM and amounting to a reduction of 12% to 17% from BS dimensions. The clinical impact of these changes is limited, given the reduced visibility of these areas of the mouth. Nonetheless, the preservation of tissue contours in these areas may still be of importance, allowing less food impaction, better access for hygiene, and better maintenance of the restorations. Furthermore, the presented protocol has a clear advantage in terms

of treatment duration, as it was able to provide final restorations in 3 to 4 months, thus shortening the treatment time compared to a delayed protocol.

It is difficult to put the amount of encountered resorption in perspective, given the limited data available in the scientific literature for this particular clinical scenario. However, in a human study, Schropp et al assessed the extent of soft tissue contour resorption after extraction without biomaterial on 46 patients by comparing casts before and 12 months after extraction.¹⁸ They found a 50% ridge resorption at 1 year, corresponding to a horizontal loss of 5 to 7 mm. The vertical resorption yielded a 1-mm collapse. These results correspond to 4× more (horizontally) and 2× more (vertically) collapse than the results observed in the present article. As far as the present authors are concerned, no comparable studies reporting on soft tissue collapse after socket preservation on molar extraction sites were found, which prevents making any scientific conclusion with regard to superiority of soft tissue stability compared to socket preservation alone.

Nevertheless, the use of combined slow resorbable bone substitute (xenograft material) and a rigid fitted mechanical barrier seems to provide a noninvasive and efficient treatment strategy to maintain peri-implant volume. The expected role of the SSA abutment is to provide mechanical support and prevent peri-implant soft tissue collapse.

With regard to the radiographic outcomes, the values at 2Y correlate

well with those reported in other investigations that evaluated the outcome of immediate implants in molar sites with mean DIB values under 1 mm.^{19,20}

In a recent study, Alexopolou et al²¹ analyzed initial and follow-up CBCT scans to determine bone volume variations when immediate implant placement in the molar region was combined with an SSA abutment. Over 1 to 5 years of follow-up in 27 patients, insignificant horizontal and vertical bone resorption was observed, regardless of implant type (bone level or tissue level) or location (maxilla or mandible). These promising results are in concordance with the present findings and, if confirmed, suggest that utilizing SSA abutments in implants immediately placed in molar sites would reduce the collapse of surrounding hard and soft tissues.

It must be kept in mind that a strict clinical protocol was applied, and implants were only placed in molar sites where there was enough apical bone to stabilize the implant appropriately. It has been reported that immediate implants may have a higher rate of implant failure when compared to implants placed in healed bone, and therefore precautions must be taken to assure sufficient primary stability.²²

It is also important to remember that the cases included in the present study were treated between 2013 and 2016. Since then, the clinical protocol has evolved, increasing clinical awareness of two key parameters: minimally invasive extraction strategy and optimization of the transmucosal design of the SSA.

Indeed, digital abutment design through a chairside system was not optimized at the time of the present study, resulting in an acceptable but inconsistent fit between the GM and the SSA abutment, which could eventually lead to lack of tissue support and stability. Although CAD/CAM SSA has the strong advantage of digital production with a highly polished and biocompatible surface, it remains at this point a technique that shows some limitations. Indeed, it requires technological skills and chairside equipment that are not available in every dental office. At present, the direct chairside, conventional technique using flowable composite appears as a cost- and time-efficient alternative for providing the surgical site with the same clinical and biologic benefits.

The most important limitation of the present investigation was the lack of a control group, which could have provided further information on the possible added benefits of utilizing an SSA in terms of soft and hard tissue stability. Similarly, no information was provided on the buccal bone stability nor the BS radiographic bone levels at the time of crown installation. Nevertheless, the present investigation provides valid information on the soft tissue dimensional stability after the use of CAD/CAM-generated customized healing abutments, proving to be an effective treatment for the preservation of tissue contours and having stable interproximal bone levels after 2 years.

Conclusions

The use of CAD/CAM-generated customized healing abutments in immediate molar sites yielded minimal hard and soft tissue changes at the 2-year follow-up.

Acknowledgments

The authors declare no conflicts of interest

References

1. Feine J, Abou-Ayash S, Al Mardini M, et al. Group 3 ITI Consensus Report: Patient-reported outcome measures associated with implant dentistry. *Clin Oral Implants Res* 2018;29(suppl 16):s270–s275.
2. Wittneben JG, Wismeijer D, Brägger U, Joda T, Abou-Ayash S. Patient-reported outcome measures focusing on aesthetics of implant- and tooth-supported fixed dental prostheses: A systematic review and meta-analysis. *Clin Oral Implants Res* 2018;29(suppl 16):s224–s240.
3. Huynh-Ba G, Oates TW, Williams MAH. Immediate loading vs. early/conventional loading of immediately placed implants in partially edentulous patients from the patients' perspective: A systematic review. *Clin Oral Implants Res* 2018;29(suppl 16):s255–s269.
4. Cosyn J, De Lat L, Seyssens L, Doornewaard R, Deschepper E, Vervaeke S. The effectiveness of immediate implant placement for single tooth replacement compared to delayed implant placement: A systematic review and meta-analysis. *J Clin Periodontol* 2019;46(suppl 21):s224–s241.
5. De Rouck T, Collys K, Cosyn J. Single-tooth replacement in the anterior maxilla by means of immediate implantation and provisionalization: A review. *Int J Oral Maxillofac Implants* 2008;23:897–904.
6. Sanz-Sánchez I, Sanz-Martín I, Figuero E, Sanz M. Clinical efficacy of immediate implant loading protocols compared to conventional loading depending on the type of the restoration: A systematic review. *Clin Oral Implants Res* 2015;26:964–982.

7. Ketabi M, Deporter D, Atenafu EG. A systematic review of outcomes following immediate molar implant placement based on recently published studies. *Clin Implant Dent Relat Res* 2016;18:1084–1094.
8. Finelle G, Lee SJ. Guided immediate implant placement with wound closure by computer-aided design/computer-assisted manufacture sealing socket abutment: Case report. *Int J Oral Maxillofac Implants* 2017;32:e63–e67.
9. Finelle G, Sanz-Martín I, Knafo B, Figuero M, Popelut A. Digitalized CAD/CAM protocol for the fabrication of customized sealing socket healing abutments in immediate implants in molar sites. *Int J Comput Dent* 2019;22:187–204.
10. Sanz-Martín I, Sailer I, Hämmerle CH, Thoma DS. Soft tissue stability and volumetric changes after 5 years in pontic sites with or without soft tissue grafting: A retrospective cohort study. *Clin Oral Implants Res* 2016;27:969–974.
11. Sanz Martín I, Benic GI, Hämmerle CH, Thoma DS. Prospective randomized controlled clinical study comparing two dental implant types: Volumetric soft tissue changes at 1 year of loading. *Clin Oral Implants Res* 2016;27:406–411.
12. De Rouck T, Collys K, Cosyn J. Immediate single-tooth implants in the anterior maxilla: A 1-year case cohort study on hard and soft tissue response. *J Clin Periodontol* 2008;35:649–657.
13. Raes F, Cosyn J, Crommelinck E, Coessens P, De Bruyn H. Immediate and conventional single implant treatment in the anterior maxilla: 1-year results of a case series on hard and soft tissue response and aesthetics. *J Clin Periodontol* 2011;38:385–394.
14. Block MS, Mercante DE, Lirette D, Mohamed W, Ryser M, Castellon P. Prospective evaluation of immediate and delayed provisional single tooth restorations. *J Oral Maxillofac Surg* 2009;67(suppl 11):s89–s107.
15. Donos N, Horvath A, Mezzomo LA, Dedi D, Calciolari E, Mardas N. The role of immediate provisional restorations on implants with a hydrophilic surface: A randomised, single-blind controlled clinical trial. *Clin Oral Implants Res* 2018;29:55–66.
16. Chan HL, George F, Wang IC, Suárez López Del Amo F, Kinney J, Wang HL. A randomized controlled trial to compare clinical esthetic outcomes of immediately placed implants with and without immediate provisionalization. *J Clin Periodontol* 2019;46:1061–1069.

17. Sanz M, Lindhe J, Alcaraz J, Sanz-Sanchez I, Cecchinato D. The effect of placing a bone replacement graft in the gap at immediately placed implants: A randomized clinical trial. *Clin Oral Implants Res* 2017;28:902–910.
18. Schropp L, Wenzel A, Kostopoulos L, Karring T. Bone healing and soft tissue contour changes following single-tooth extraction: A clinical and radiographic 12-month prospective study. *Int J Periodontics Restorative Dent* 2003;23:313–323.
19. Tallarico M, Xhanari E, Pisano M, Gatti F, Meloni SM. Molar replacement with 7 mm-wide diameter implants: To place the implant immediately or to wait 4 months after socket preservation? 1 year after loading results from a randomised controlled trial. *Eur J Oral Implantol* 2017;10:169–178.
20. Checchi V, Felice P, Zucchelli G, et al. Wide diameter immediate post-extractive implants vs delayed placement of normal-diameter implants in preserved sockets in the molar region: 1-year post-loading outcome of a randomised controlled trial. *Eur J Oral Implantol* 2017;10:263–278.
21. Alexopoulou M, Lambert F, Knafo B, Popelut A, Vandenberghe B, Finelle G. Immediate implant in the posterior region combined with alveolar ridge preservation and sealing socket abutment: A retrospective 3D radiographic analysis. *Clin Implant Dent Relat Res* 2021. Epub ahead of print.
22. Cosyn J, De Lat L, Seyssens L, Doornewaard R, Deschepper E, Vervaeke S. The effectiveness of immediate implant placement for single tooth replacement compared to delayed implant placement: A systematic review and meta-analysis. *J Clin Periodontol* 2019;46(suppl 21):s224–s241.