

Gary Finelle
 Dimitrios E. V. Papadimitriou
 André B. Souza
 Negin Katebi
 German O. Gallucci
 Mauricio G. Araújo

Peri-implant soft tissue and marginal bone adaptation on implant with non-matching healing abutments: micro-CT analysis

Authors' affiliations:

Gary Finelle, Dimitrios E. V. Papadimitriou, German O. Gallucci, Division of Regenerative and Implant Sciences, Department of Restorative Dentistry and Biomaterials Sciences, Harvard School of Dental Medicine, Boston, MA, USA
 André B. Souza, Mauricio G. Araújo, Department of Dentistry, State University of Maringa, Parana, Brazil
 Negin Katebi, Department of Developmental Biology, Harvard School of Dental Medicine, Boston, MA, USA

Corresponding author:

German O. Gallucci, DMD, Dr Med Dent PhD
 Department of Restorative Dentistry and Biomaterials Sciences, Harvard School of Dental Medicine Harvard University, 188, Longwood Avenue, 02115 Boston, MA, USA
 Tel.: +16174325764
 Fax: +16174320901
 e-mail: german_gallucci@hsdm.harvard.edu

Key words: crestal bone remodeling, healing abutment, horizontal bone apposition, horizontal offset, implant diameter, platform switching

Abstract

Purpose: To assess (i) the outcome of changing the horizontal-offset dimension on the peri-implant soft tissues and the crestal bone and (ii) the effect of different healing abutments (flared vs. straight) on the marginal peri-implant soft tissues and crestal bone.

Materials and Methods: Two-piece dental implants diameters of 3.5 and 4.5 mm were placed at least 1 mm subcrestal in five beagle dogs. Three different investigational groups: (i) 3.5-mm-diameter implant with narrow healing abutment (3.5N), (ii) 4.5-mm-diameter implant with narrow healing abutment (4.5N), and (iii) 3.5-mm-diameter implant with wide healing abutment (3.5W), were assessed. After 4 months of healing, the vertical distance from the marginal crestal bone (MB) to the implant shoulder (IS); the vertical distance from the IS to the first bone-to-implant contact; and the horizontal distance of bone ingrowth on the implant platform were measured with a high-resolution micro-CT (Xradia MicroXCT-200 system).

Results: Implants with a narrow healing caps showed an interproximal MB located between 0 and 1 mm above the implant shoulder, while the 3.5W group exhibits a mean value -0.50 mm. As all implants in group 3.5N presented a fBIC located at the level of the IS. For the 4.5N group, the mean fBIC-IS distance was -0.52 mm apically to the IS. For the 3.5WC group, the mean fBIC-IS distance was -1.42 mm. Horizontal bone apposition was only observed for the 3.5N group and the 4.5N group.

Conclusion: The dimension of the horizontal offset would play a minimal role in reducing bone remodeling, whereas the configuration of the transmucosal component would directly influence marginal bone remodeling.

The bone and peri-implant mucosal reactions around titanium implants have been studied in several animal experiments (Buser et al. 1992; Listgarten 1996; Hermann et al. 2001; Shin et al. 2006). Marginal bone remodeling of 1 mm in the first year following prostheses delivery has been cited as part of the radiographic criteria for successful osseointegration (Albrektsson & Zarb 1993). Different theories have been proposed to examine this phenomenon. One theory focuses on stress concentration on the coronal part of the implant (Pilliar et al. 1991), while a contrasting theory advocates the opinion that crestal bone remodeling is a result of localized inflammation within the soft tissue located at the implant-abutment interface and is a consequence of the soft tissue's attempt to establish a mucosal barrier (biologic width)

around the crestal part of the implant (Ericson et al. 1995; Abrahamsson et al. 1998).

Nevertheless, Lazzara and Porter (2006) were the first one to define this biomechanical concept under the name of "platform switching". According to his study, when the outer edge of the implant-abutment interface is horizontally repositioned inwardly and away from the outer edge of the implant platform, the crestal bone remodeling is altered vertically. This was evident on radiographs at mesial and distal sites of osseointegrated implants (Lazzara & Porter 2006). The biologic rationale for the platform switching concept as suggested by the author is that deliberate mismatching of the implant platform and abutment diameter repositions the inflammatory cell infiltrate zone surrounding the abutment further away from crestal bone and relocates the inflamma-

Date:

Accepted 5 December 2013

To cite this article:

Finelle G, Papadimitriou DEV, Souza AB, Katebi N, Gallucci GO, Araújo MG. Peri-implant soft tissue and marginal bone adaptation on implant with non-matching healing abutments: micro-CT analysis.
Clin. Oral Impl. Res. 00, 2014, 1–5
 doi: 10.1111/clr.12328

tory infiltrate within an approximately ≤ 90 -degree confined area of exposure, instead of a ≤ 180 -degree area of direct exposure to the surrounding hard and soft tissues (Lazzara & Porter 2006). Subsequently, different authors have presented similar results on animal (Jung et al. 2008) and human studies (Cappiello et al. 2008; Canullo et al. 2009, 2010). On the other hand, several animal (Becker et al. 2007; Becker et al. 2009) and human studies (Nentwig 2004; Enkling et al. 2011) have failed to find a significant difference in bone remodeling between platform and non-platform switching implants. Finally, one recent systematic review found a beneficial effect of platform switching implants on peri-implant marginal bone (Al-Nsour et al. 2012) and another study had previously shown that platform switching may preserve interimplant bone height and soft tissue levels (Atieh et al. 2010). In that study, they also suggest that the degree of marginal bone resorption is inversely related to the extent of the implant-abutment mismatch (Atieh et al. 2010). In contrast, a different systematic review failed to find any effectiveness of platform switching concept in the preservation of marginal bone (Bateli et al. 2011).

The aim of this study in dogs was to assess (i) the outcome of changing the horizontal-offset dimension on the peri-implant soft tissues and the crestal bone and (ii) the effect of different-shaped healing abutments (flared vs. straight design) on the marginal peri-implant soft tissues and the crestal bone through the use of different transmucosal designs.

Material and methods

The study was a two-centered animal study performed at the University of Maringá, Parana, Brazil, and Harvard School of Dental Medicine. The ethical committee of the State University of Maringá, Brazil, approved the research protocol (N° 062/2010). In addition, this approval was revised and deemed acceptable according to the Harvard Medical Area Standing Committee on Animals and the Office for Research Subject Protection of Harvard Medical School.

Two-piece dental implants (DENTSPLY Implants, Waltham, MA, USA) with two different endosteal diameters of 3.5 mm and 4.5 mm were placed 1 mm subcrestal. A conical Morse taper internal abutment connection secured the positioning of the healing abutment on the fixture. The abutments used in this study had similar dimensions at the level of the implant shoulder. However, they had

different shapes (flared vs. straight design) and different coronal diameters at the transmucosal portion. This resulted in a horizontal offset and consequently a gradual horizontal displacement of the implant-abutment interface. These combinations of implant diameter and healing abutment morphology resulted in three different investigational groups: (i) 3.5-mm-diameter implant with narrow healing abutment (3.5N), (ii) 4.5-mm-diameter implant with narrow healing abutment (4.5N), (iii) 3.5-mm-diameter implant with wide healing abutment (3.5W) (Fig. 1).

Five beagle dogs aged between 12–15 months weighting from 10 to 12 kg were used in this study. The dogs were anesthetized with intravenously administered ketamine 10% (8 mg/kg; Agener União, São Paulo, Brazil). The mandibular premolars (P1–P4) and the first molar (M1) were extracted. Once every second day, the animals were exposed to mechanical tooth cleaning using a toothbrush and dentifrice. Following a 3-month healing period, three fixtures were installed in each mandibular side (diameter: 3.5 mm or 4.5 mm). A minimal distance of 4 mm was maintained between each implant shoulder. The abutment connection was transmucosal, and it was placed at the time of the implant placement. Each implant received a healing abutment with a diameter of 2.5 mm at the level of the implant shoulder. The implants were randomly allocated on each side of the mandible using permuted block randomization protocol with a block size of six. Each animal received six implants in total (three left and three right mandibular locations). On

each side, implants from each group received one of the two abutment designs. Post-operative radiographs were obtained of all implants. Radiographs were obtained in a standardized manner immediately after fixture installation according to a previously described technique (Hermann et al. 2001). At this point, a 12-week period of plaque control was initiated.

After 4 months of healing, the dogs were euthanized with an overdose of ketamine and perfused, through the carotid arteries, with a fixative containing a mixture of 5% glutaraldehyde and 4% formaldehyde (Karnovsky 1965). The mandibles were sectioned and tissue samples, comprising the implant and the surrounding soft and hard peri-implant tissues, were examined with radiographic computed microtomography (micro-CT) analysis (Fig. 2). Micro-CT imaging was subjected to a high-resolution micro-CT analysis (Xradia

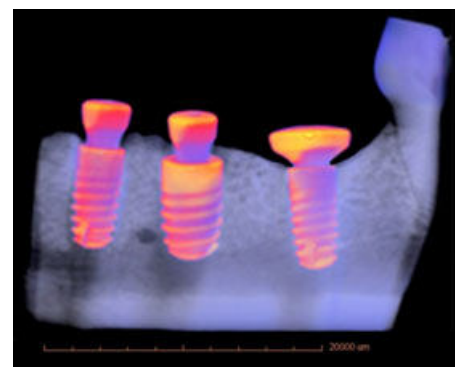


Fig. 2. 3D reconstruction image generated by the Xradia scanner (3D viewing software).

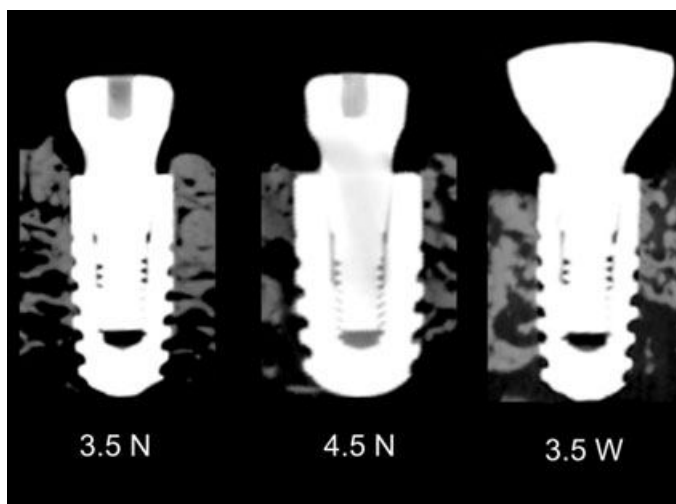


Fig. 1. Mesio-distal section from computed microtomography representing implants of each group: 3.5N, 3.5W, 4.5N. 3.5N, 3.5-mm-diameter implant, 8-mm-length, narrow healing abutment; 3.5W, 3.5-mm-diameter implant, 8-mm-length, wide healing abutment; 4.5N, 4.5-mm-diameter implant, 8-mm-length, narrow healing abutment.

MicroXCT-200 system, Pleasanton, CA, USA). The following parameters were used for acquisition: 1600 views in a 360-degree rotation with an exposure time of 7 s per radiograph. For source setting, the system was set at 80 kV/8 W and a LE#5 filter was used. The source and detector were kept at the same distance for scanning all samples. In order to cover the field of view of the samples, the optical system was set to obtain a pixel size of 29.828 μm. The 3D viewing software provided with the Xradia scanner was used to generate all 3D images (Carl Zeiss Microscopy GmbH Carl Zeiss Promenade, Jena, Germany). To reduce file sizes and improve signal-to-noise ratio, the images were reconstructed with 2 × 2 pixel binning. For each image, the window-level setting was adjusted and saved as a single frame in jpg format.

The following landmarks were identified and were used for measurements: implant shoulder (IS), marginal crestal bone (MB), first bone-to-implant contact at the vertical axis of the implant (fBIC), horizontal bone apposition at the horizontal axis on the implant platform (HBA) (Fig. 3). The following measurements were performed using a 3D viewer software provided with Xradia scanner in both mesial and distal aspects of each implant: MB-IS was defined as the vertical distance from the marginal crestal bone to the implant shoulder; IS-fBIC was defined as the vertical distance from the implant shoulder to the fBIC (when IS and fBIC coincided, the value was deemed as zero); HBA was defined as the horizontal distance on the implant platform to the greatest inward extent of bone ingrowth on the implant shoulder.

For the descriptive statistics, mesial and distal values were combined to calculate the mean value and standard error (SE) of MB-IS, fBIC-IS, and HBA.

Results

MB-IS analysis

Mean values for interproximal MB for each group are presented in Fig. 4. When the MB was located coronal to the IS, a positive (+) value was given, where a negative (-) value when located apically to the IS. Narrow healing abutments groups (3.5N and 4.5N) presented positive mean values of 0.84 mm (SE = 0.13) and 0.29 mm (SE = 0.36), respectively. Implants with a narrow healing abutments showed an interproximal MB located between 0 and 1 mm above the implant shoulder, while the 3.5W group exhibits a mean value -0.50 mm (SE = 0.30) (Table 1).

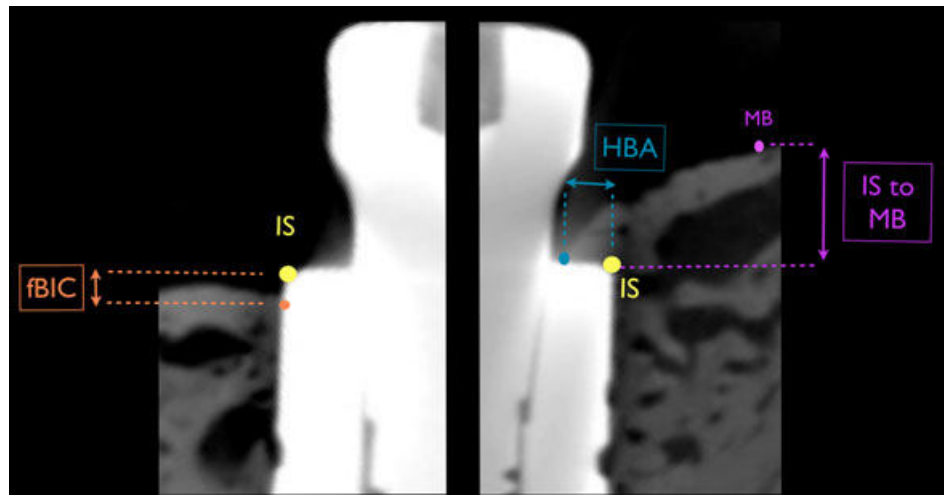


Fig. 3. Schematic drawings illustrating the landmarks used for the radiographic measurements. IS, implant shoulder; MB, marginal crestal bone; fBIC, first bone-to-implant contact at the vertical axis of the implant; MB-IS, vertical distance from the marginal crestal bone to the implant shoulder; IS-fBIC, vertical distance from the implant shoulder to the fBIC (when IS and fBIC coincided, the value was deemed as zero); HBA, horizontal bone apposition at the horizontal axis on the implant platform (when bone ingrowth was not observed on the implant platform, the value was deemed as zero).

Table 1. Mean values of MB to IS, IS to fBIC, IS to HBA, at mesial and distal aspects (in mm)

	N	Mean MB to IS	Mean IS to fBIC	Mean HBA
3.5NC	6	0.84 mm (0.13)	0.00 mm (0)	0.17 mm (0.05)
4.5NC	12	0.29 mm (0.36)	-0.52 mm (0.27)	0.18 mm (0.07)
3.5WC	6	-0.50 mm (0.30)	-1.42 mm (0.34)	0.00 mm (0)

Data are expressed as mean ± standard errors (SE).

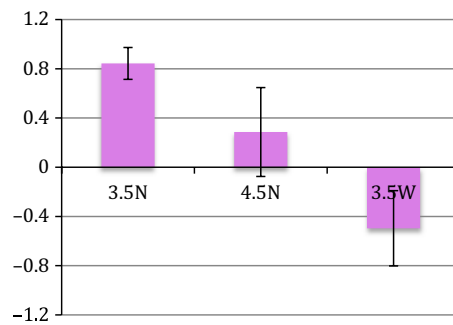


Fig. 4. Mean values (mm) of distance from interproximal marginal bone position to implant shoulder (MB-IS) for each group. 3.5N, 3.5-mm-diameter implant, 8-mm-length, narrow healing abutment; 3.5W, 3.5-mm-diameter implant, 8-mm-length, wide healing abutment; 4.5N, 4.5-mm-diameter implant, 8-mm-length, narrow healing abutment; data are expressed as mean (colored bars) ± standard deviation (SE) (black line).

For the fBIC-IS analysis

The fBIC-IS mean values are described in Fig. 5. A zero value was given when the fBIC was located at the IS level and a negative (-) value when fBIC was found apical to the IS. All implants in group 3.5N presented a fBIC located at the level of the IS. For the 4.5N group, the mean fBIC-IS distance was of -0.52 mm (SE = 0.27). For the 3.5WC group, the mean fBIC-IS distance was of -1.42 mm (SE = 0.34) (Table 1).

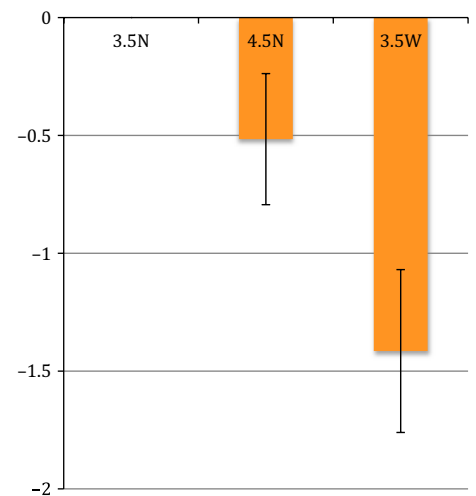


Fig. 5. Mean values (mm) of distance from implant shoulder to the first bone-to-implant contact (IS-fBIC) for each group. 3.5N, 3.5-mm-diameter implant, 8-mm-length, narrow healing abutment; 3.5W, 3.5-mm-diameter implant, 8-mm-length, wide healing abutment; 4.5N, 4.5-mm-diameter implant, 8-mm-length, narrow healing abutment; data are expressed as mean (colored bars) ± standard deviation (SE) (black line).

For the HBA analysis

The HBA mean values are reported in Fig. 6. A zero value was given when the fBIC was found at the IS or apically in the vertical axis, where a positive (+) value when horizontal bone

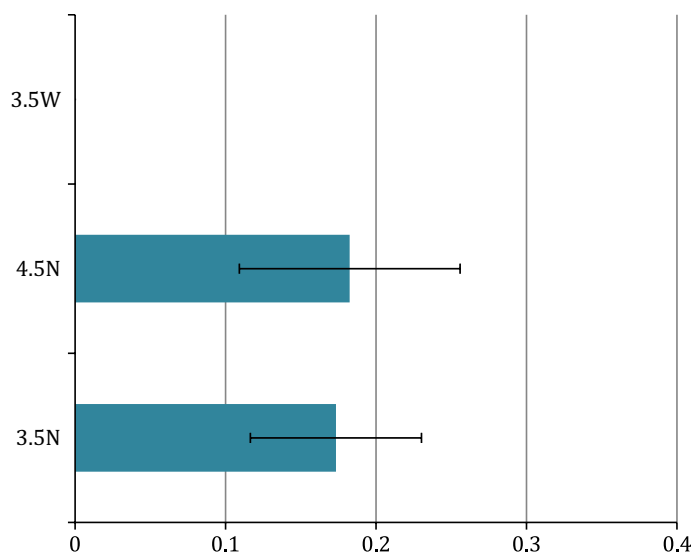


Fig. 6. Mean values (mm) of horizontal bone apposition (HBA) for each group. 3.5N, 3.5-mm-diameter implant, 8-mm-length, narrow healing abutment; 3.5W, 3.5-mm-diameter implant, 8-mm-length, wide healing abutment; 4.5N, 4.5-mm-diameter implant, 8-mm-length, narrow healing abutment; data are expressed as mean (colored bars) \pm standard deviation (SE) (black line).

apposition was found onto the implant shoulder.

For the 3.5N group, the interproximal HBA mean value was 0.17 mm (SE = 0.05). Similarly, in the 4.5N group, a mean of 0.18 mm (SE = 0.07) of horizontal bone apposition was found. On the contrary, none of the implants from the 3.5W group revealed any horizontal bone apposition on their platform (Table 1).

Discussion

The purpose of the present animal study was to assess the influence of different healing abutments and transmucosal designs (shapes and diameter) on crestal bone.

When reviewing the animal studies on platform switching, Becker et al. (2007) found that initially, at 7, 14, and 28 days, the mean “implant shoulder to the apical extension of the long junctional epithelium” values were significantly lower at implants with reduced diameter healing abutments. However, after 28 days of healing, both groups of platform and non-platform switched implants revealed significantly increased mean “implant shoulder to the alveolar bone crest” values at the buccal aspect of the alveolar bone. The

difference in “implant shoulder to the most coronal level of bone in contact with the implant” and “implant shoulder to the level of the alveolar bone crest” between the groups was not significant (Becker et al. 2007).

The same author in a later study with a longer follow-up period of 6 months found that bone remodeling was minimal in both groups and platform switching may not be of crucial importance for maintenance of the crestal bone level (Becker et al. 2009).

In contrast, Farronato et al. (2011) found that the platform switching concept resulted in less marginal bone resorption after 4 months of healing than that encountered at implants with matching diameter abutments (Farronato et al. 2011).

In another animal study, they evaluated the radiographic crestal bone-level changes around platform switching implants placed submucosal or transmucosal at three different levels relative to the alveolar crest (Jung et al. 2008). Radiographic analysis showed very little bone loss and a slight increase in bone level for implants placed at the level of the crest or 1 mm above. The greatest bone loss occurred at implants placed 1 mm below the bone crest.

In the present study, the interproximal height of the MB seemed to be significantly more stable with narrow healing abutments. Similarly, the results demonstrated that implants from the 3.5N group had a fBIC at the shoulder level, whereas the other groups revealed a more apical fBIC (Table 1).

One interesting finding was the horizontal bone apposition on the implant shoulder. This was observed only in the implants with a narrow healing abutment without respect to the implant diameter (0.17 mm for 3.5N group and 0.18 mm for 4.5N group). Conversely, the 3.5-mm-diameter implants with the wide healing abutment revealed any horizontal bone apposition on their platform. These results could be explained by the morphological configuration of the implant–abutment interface. In this context, narrow diameter healing abutments forming a 90° angle with the implant platform allow for more vertical and horizontal space to accommodate the connective tissue of the peri-implant biologic width. Thus, the soft tissue can adapt closer to the center of the implant and vertically up the abutment allowing space on the platform for the marginal bone to heal over the implant shoulder.

Conversely, when using a wide healing abutment, the angle formed between the abutment and the implant shoulder decreases leaving less space to establish a proper peri-implant biologic width. Here, the adaptation of a peri-implant biologic width will establish further away from the implant center resulting in more marginal bone remodeling. Atieh suggested that the degree of marginal bone resorption is inversely related to the extent of the implant–abutment mismatch (Atieh et al. 2010).

In conclusion, results from this study suggest that the dimension of the horizontal offset would play a minimal role in reducing bone remodeling, whereas the configuration of the transmucosal component would directly influence marginal bone remodeling.

Acknowledgements: This study was supported by a research grant from DENTSPLY Implants. The entire rights, title, interest in and to all investigator, and results owned by Harvard University.

References

- Abrahamsson, I., Berglundh, T. & Lindhe, J. (1998) Soft tissue response to plaque formation at different implant systems. A comparative study in the dog. *Clinical Oral Implants Research* 9: 73–79.
- Albrektsson, T. & Zarb, G.A. (1993) Current interpretations of the osseointegrated response: clinical significance. *The International journal of prosthodontics* 6: 95–105.
- Al-Nsour, M.M., Chan, H.-L. & Wang, H.-L. (2012) Effect of the platform-switching technique on preservation of peri-implant marginal bone: a systematic review. *The International*

- journal of oral & maxillofacial implants* **27**: 138–145.
- Atieh, M.A., Ibrahim, H.M. & Atieh, A.H. (2010) Platform Switching for Marginal Bone Preservation Around Dental Implants: a Systematic Review and Meta-Analysis. *Journal of Periodontology* **81**: 1350–1366.
- Bateli, M., Att, W. & Strub, J.R. (2011) Implant neck configurations for preservation of marginal bone level: a systematic review. *The International journal of oral & maxillofacial implants* **26**: 290–303.
- Becker, J., Ferrari, D., Hertel, M., Kirsch, A., Schaefer, A. & Schwarz, F. (2007) Influence of platform switching on crestal bone changes at non-submerged titanium implants: a histomorphometrical study in dogs. *Journal of Clinical Periodontology* **34**: 1089–1096.
- Becker, J., Ferrari, D., Mihatovic, I., Sahm, N., Schaefer, A. & Schwarz, F. (2009) Stability of crestal bone level at platform-switched non-submerged titanium implants: a histomorphometrical study in dogs. *Journal of Clinical Periodontology* **36**: 532–539.
- Buser, D., Weber, H.P., Donath, K., Fiorellini, J.P., Paquette, D.W. & Williams, R.C. (1992) Soft tissue reactions to non-submerged unloaded titanium implants in beagle dogs. *Journal of Periodontology* **63**: 225–235.
- Canullo, L., Fedele, G.R., Iannello, G. & Jepsen, S.R. (2009) Platform switching and marginal bone-level alterations: the results of a randomized-controlled trial. *Clinical Oral Implants Research* **21**: 115–121.
- Canullo, L., Pellegrini, G., Allievi, C., Trombelli, L., Annibaldi, S. & Dellavia, C. (2010) Soft tissues around long-term platform switching implant restorations: a histological human evaluation. Preliminary results. *Journal of Clinical Periodontology* **38**: 86–94.
- Cappiello, M., Luongo, R., Di Iorio, D., Bugea, C., Cocchetto, R. & Celletti, R. (2008) Evaluation of peri-implant bone loss around platform-switched implants. *The International Journal of Periodontics & Restorative Dentistry* **28**: 347–355.
- Enkling, N., Jöhren, P., Klimberg, V., Bayer, S., Mericske-Stern, R. & Jepsen, S. (2011) Effect of platform switching on peri-implant bone levels: a randomized clinical trial. *Clinical Oral Implants Research* **22**: 1185–1192.
- Ericsson, I., Persson, L.G., Berglundh, T., Marinello, C.P., Lindhe, J. & Klinge, B. (1995) Different types of inflammatory reactions in peri-implant soft tissues. *Journal of Clinical Periodontology* **22**: 255–261.
- Farronato, D., Santoro, G., Canullo, L., Botticelli, D., Maiorana, C. & Lang, N.P. (2011) Establishment of the epithelial attachment and connective tissue adaptation to implants installed under the concept of “platform switching”: a histologic study in minipigs. *Clinical Oral Implants Research* **23**: 90–94.
- Hermann, J.S., Schoolfield, J.D., Nummikoski, P.V., Buser, D., Schenk, R.K. & Cochran, D.L. (2001) Crestal bone changes around titanium implants: a methodologic study comparing linear radiographic with histometric measurements. *The International journal of oral & maxillofacial implants* **16**: 475–485.
- Jung, R.E., Jones, A.A., Higginbottom, F.L., Wilson, T.G., Schoolfield, J., Buser, D., Hämmerle, C.H.F. & Cochran, D.L. (2008) The Influence of Non-Matching Implant and Abutment Diameters on Radiographic Crestal Bone Levels in Dogs. *Journal of Periodontology* **79**: 260–270.
- Karnovsky, M.J. (1965) A formaldehyde–glutaraldehyde fixative of high osmolarity for use in electron microscopy. *Journal of Cell Biology* **27**: 137A–138A.
- Lazzara, R.J. & Porter, S.S. (2006) Platform switching: a new concept in implant dentistry for controlling postrestorative crestal bone levels. *The International Journal of Periodontics & Restorative Dentistry* **26**: 9–17.
- Listgarten, M.A. (1996) Soft and hard tissue response to endosseous dental implants. *The Anatomical record* **245**: 410–425.
- Nentwig, G.H. (2004) The Ankylos implant system: concept and clinical application. *The Journal of Oral Implantology* **30**: 171–177.
- Pilliar, R.M., Deporter, D.A., Watson, P.A. & Valiquette, N. (1991) Dental implant design—effect on bone remodeling. *Journal of Biomedical Materials Research Part B: Applied Biomaterials* **25**: 467–483.
- Shin, Y.-K., Han, C.-H., Heo, S.-J., Kim, S. & Chun, H.-J. (2006) Radiographic evaluation of marginal bone level around implants with different neck designs after 1 year. *The International journal of oral & maxillofacial implants* **21**: 789–794.