

13.8 Rehabilitating an Edentulous Maxilla with Three Separate Bridges

G. Finelle

A 55-year-old woman was referred to our clinic for implant therapy. She was healthy and had stopped smoking two years previously. Ten years before, the patient had received extensive dental treatment in both jaws. The patient reported that her dental condition had deteriorated progressively since that time. At the time of presentation, the maxillary bridge was loose. The clinical and radiographic examinations revealed a highly compromised situation for all the teeth that supported the bridge and for other teeth (Figs 1 to 4).

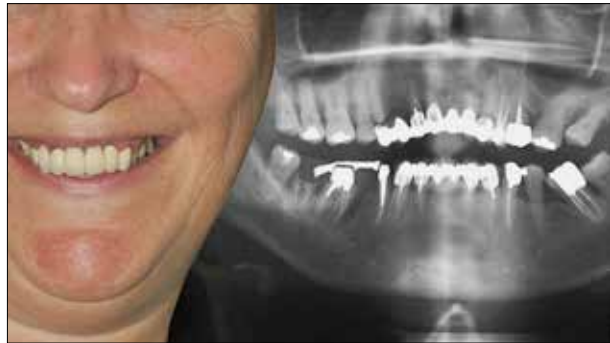

Fig 1 Patient smile and panoramic radiograph at baseline.

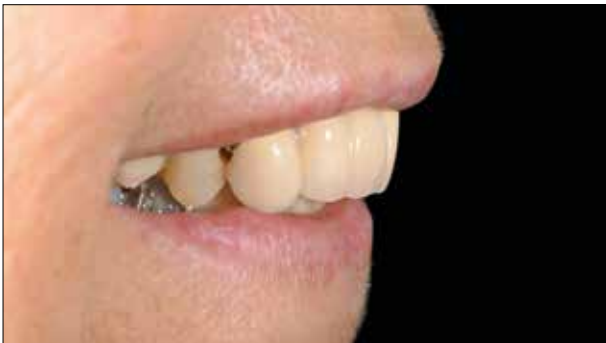

Fig 2 Profile view of the smile at baseline.

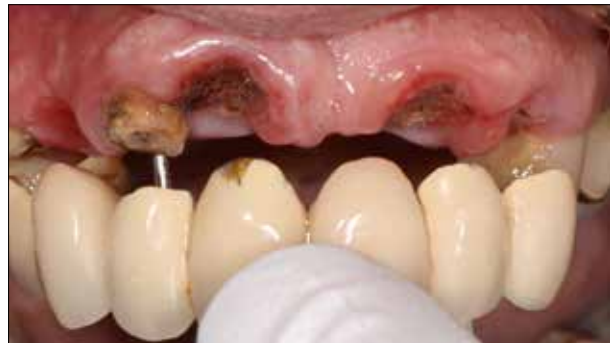

Fig 3 Intraoral baseline situation.

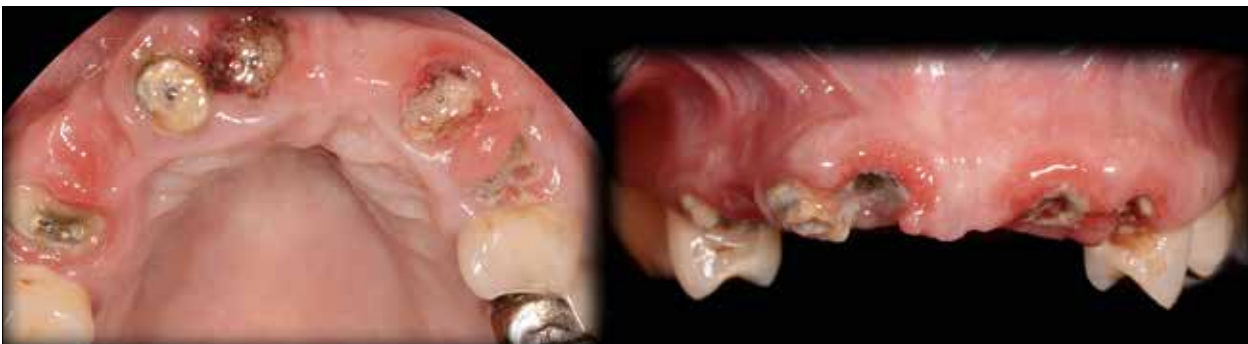

Fig 4 Intraoral situation after bridge removal (occlusal and frontal views).

Table 1 Esthetic Risk Assessment

Esthetic risk factors	Level of risk		
	Low	Medium	High
Medical status	Healthy, uneventful healing		Compromised healing
Smoking habit	Non-smoker	Light smoker (≤ 10 cigs/day)	Heavy smoker (> 10 cigs/day)
Gingival display at full smile	Low	Medium	High
Width of edentulous span	1 tooth (≥ 7 mm) ¹ 1 tooth (≥ 6 mm) ²	1 tooth (< 7 mm) ¹ 1 tooth (< 6 mm) ²	2 teeth or more
Shape of tooth crowns	Rectangular		Triangular
Restorative status of neighboring teeth	Virgin		Restored
Gingival phenotype	Low-scalloped, thick	Medium-scalloped, medium-thick	High-scalloped, thin
Infection at implant site	None	Chronic	Acute
Soft-tissue anatomy	Soft tissue intact		Soft-tissue defects
Bone level at adjacent teeth	≤ 5 mm to contact point	5.5 to 6.5 mm to contact point	≥ 7 mm to contact point
Facial bone-wall phenotype*	Thick-wall phenotype ≥ 1 mm thickness		Thin-wall phenotype < 1 mm thickness
Bone anatomy of alveolar crest	No bone deficiency	Horizontal bone deficiency	Vertical bone deficiency
Patient's esthetic expectations	Realistic expectations		Unrealistic expectations

* If three-dimensional imaging is available with the tooth in place

¹ Standard-diameter implant, regular connection

² Narrow-diameter implant, narrow connection

A detailed interdisciplinary clinical and radiographic examination was made to evaluate the prognosis of the teeth to establish a proper treatment plan. The analysis revealed chronic generalized moderate (and locally severe) periodontitis combined with numerous restoratively and endodontically compromised teeth in both jaws.

Panoramic and periapical radiographs confirmed the clinical findings, demonstrating severe restorative and periodontal damage in the entire maxilla, suggesting an implant-supported fixed full-arch rehabilitation. The treatment plan for the mandible was to retain the natural teeth, with the exception of the non-salvageable 46 and 47. An implant-supported prosthetic rehabilitation was to be provided once periodontal health was established, with periodontal recalls every 4 to 6 months.

Based on the Esthetic Risk Analysis (ERA), the case was classified as “complex,” with ten of the thirteen parameters examined falling into a risk category (Table 1).

After a thorough discussion of the situation with the patient, it was decided to pursue the following treatment plan:

1. Flapless extraction of teeth 15 to 25 and socket debridement
2. Delivery of an immediate removable partial denture
3. Generalized periodontal therapy
4. After three months of healing: 3D digital analysis, virtual planning of implant positions, and 3D-printed surgical-guide production
5. Placement of eight SLActive implants (Institut Straumann AG, Basel, Switzerland) using computer-generated surgical guides based on the combined tooth and mucosal support; simultaneous guided bone regeneration was to be provided
6. After another two months: Delivery of a full-arch screw-retained fixed provisional restoration milled from a PMMA block
7. After another two months: Final loading of the implants with definitive screw-retained segmented CAD/CAM bridges (three parts), with each framework milled from titanium and single monolithic lithium disilicate CAD/CAM crowns (e.max; Ivoclar Vivadent, Schaan, Liechtenstein) cemented to the framework at the laboratory

Initial debridement and periodontal therapy

Due to the presence of active infection and in order to obtain fully healed soft tissue at the time of implant placement, a delayed approach (twelve weeks) was chosen over immediate placement. Initial gingival and periodontal debridement was performed to reduce the intraoral bacterial load. Teeth 15 to 25 as well as 45 and 46 were extracted. A temporary removable partial denture was constructed based on a facially driven prosthetic set-up that included occlusal, functional, and esthetic consideration.

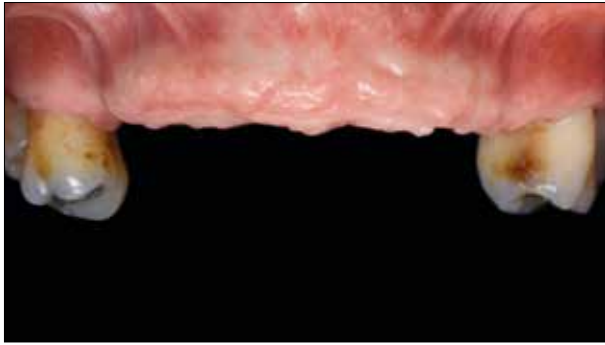

Fig 5 Healing of the maxillary ridge eight weeks after extraction.

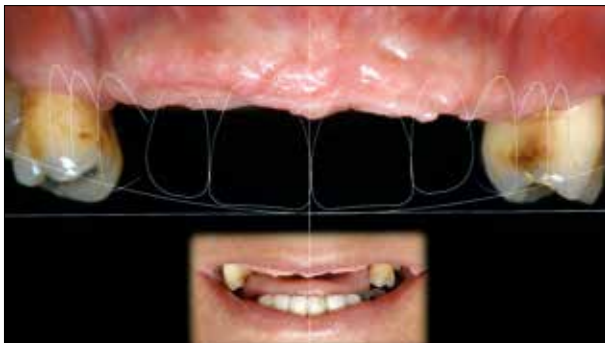

Fig 6 Digital Smile design (DSD) analysis.

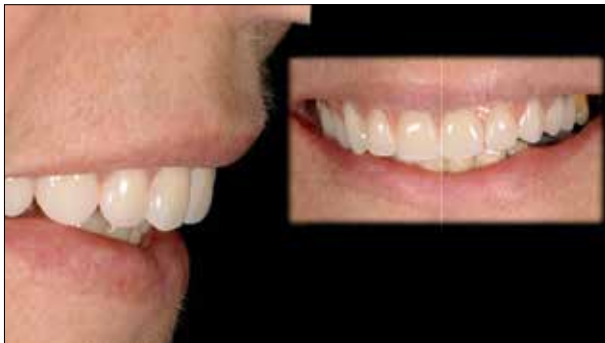

Fig 7 Delivery of the provisional removable restoration based on the DSD process.

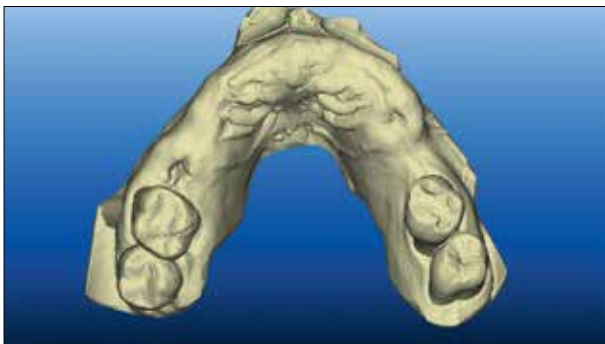


Fig 8 Surface scan of situation eight weeks after extraction.

Digital diagnosis and virtual implant planning

After eight weeks of healing (Fig 5), the clinical and esthetic analysis was reassessed to determine the patient's esthetic risk profile. At full smile, the patient presented a medium lip line displaying part of the existing gingiva in the edentulous anterior region. The patient's gingival biotype was thick, with sufficient keratinized gingiva. A digital analysis was performed to meet the following objectives:

- To confirm esthetic requirements using Digital Smile Design (DSD) analysis and a facially driven set-up (Figs 6 and 7) (Coachman 2016)
- To merge the prosthetic and esthetic (extra- and intraoral) information with the underlying bony structures using 3D planning software
- To determine the ideal 3D positions of the proposed implants in a prosthetically driven approach
- To design and fabricate a 3D-printed surgical guide based on the above-mentioned plan
- To ensure communication of the proposed treatment to all members of the dental team

Unlike a conventional diagnosis, 3D implant planning software packages (CoDiagnostiX; Dental Wings, Montreal, Canada) allows different types of clinical information to be superimposed and merged on a common planning platform for an integrated diagnosis. This allows the dental team (prosthodontist, surgeon, laboratory technician) to concurrently visualize information regarding the hard and soft tissues, the planned prosthesis, the intended implant positions, and extraoral facial references.

In this specific case, the following information was recorded:

- The 3D bone volume, using cone-beam computed tomography (CBCT; output: DICOM files)
- The clinical situation showing the teeth and soft-tissue contours through digital intraoral surface scanning (output: STL files) (Fig 8)

The intended treatment outcome with the esthetic set-up based on the DSD analysis demonstrated the ideal prosthetic situation at the end of treatment through further intraoral surface scanning (output: STL files) (Fig 9)

The digital workflow for virtual 3D planning and fabrication of a surgical guide is as follows:

1. Import and segmentation of maxillary bony structure data (from CBCT)
2. Import of maxillary surface scan to assess the position and thickness of the soft tissue relative to the bone
3. Import of a digitized ideal set-up based on the DSD facial analysis
4. Prosthetically driven implant selection and 3D positioning (Figs 10 and 11)
5. Corresponding positioning of the drilling sleeves
6. Virtual design of the surgical guide (Figs 12 and 13)
7. Export of the surgical-guide design (STL file) and drilling protocol (PDF)
8. Surgical-guide fabrication by CAD/CAM additive manufacturing (3D printing) (Fig 14)

The superimposition of the CBCT data and several STL files allows the surgeon to plan the implant procedure with a global and multidisciplinary vision of the prosthetic requirements and the soft-tissue situation.

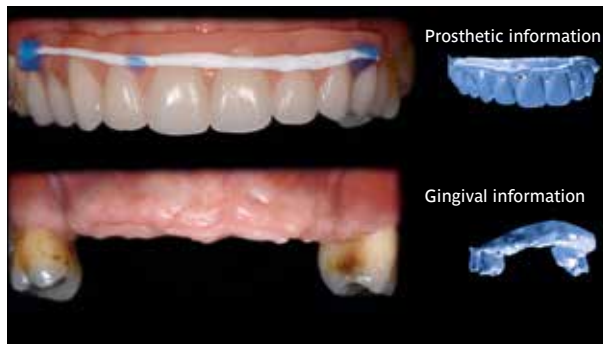

Fig 9 Digital information on the prosthetic position (esthetic set-up), position of lip line (PTFE cord), and soft-tissue position (intraoral situation).

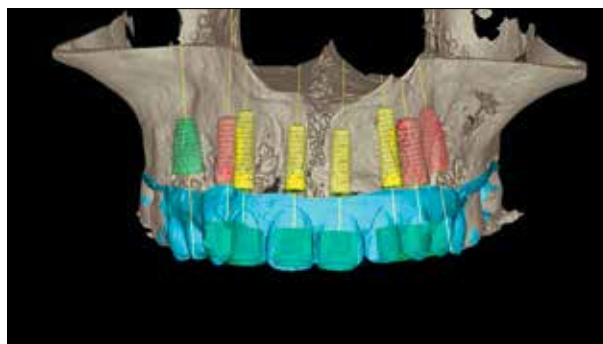


Fig 10 Prosthetically driven implant positions and the prosthetic design.

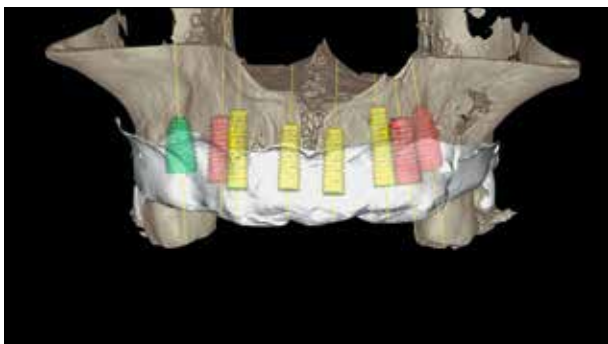


Fig 11 Implant position and the available soft tissue.

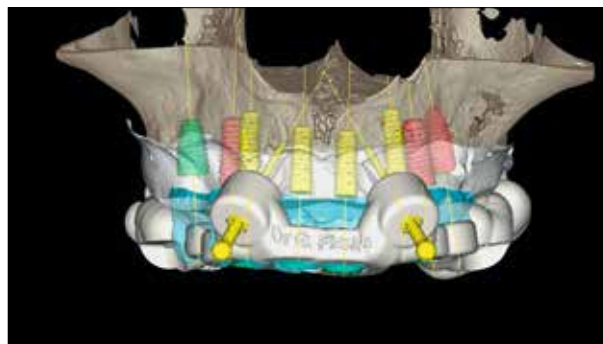


Fig 12 Design of the hybrid tooth- and mucosa-supported surgical guide.

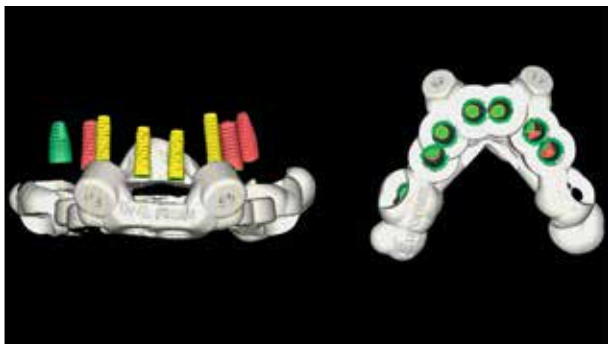


Fig 13 Surgical-guide design and the implant positions.



Fig 14 CAD/CAM-generated (3D printed) surgical guide.

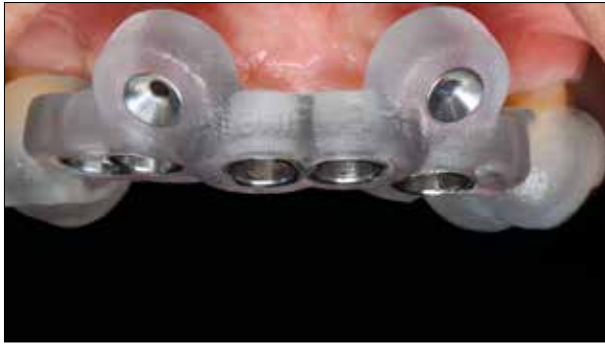


Fig 15 Seating of the surgical guide before surgery.

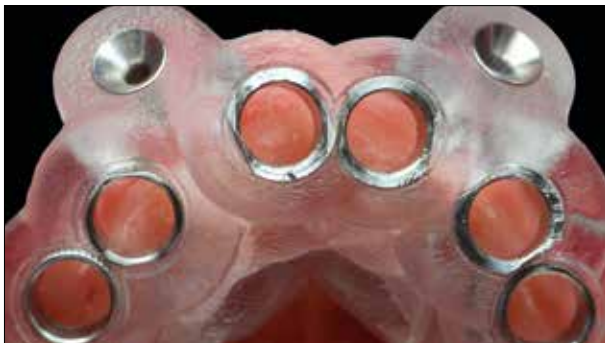

Fig 16 Occlusal view of the surgical guide in place.

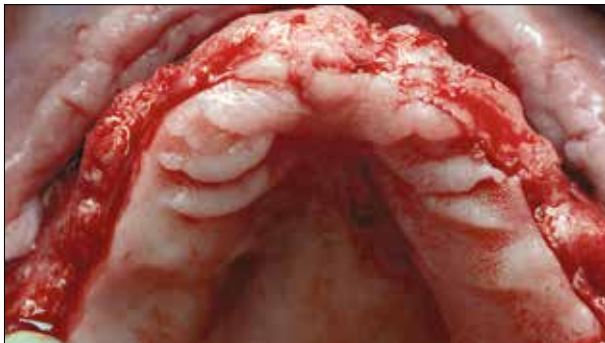

Fig 17 Palatal position of the crestal incision to optimize the supply of buccal keratinized tissue.

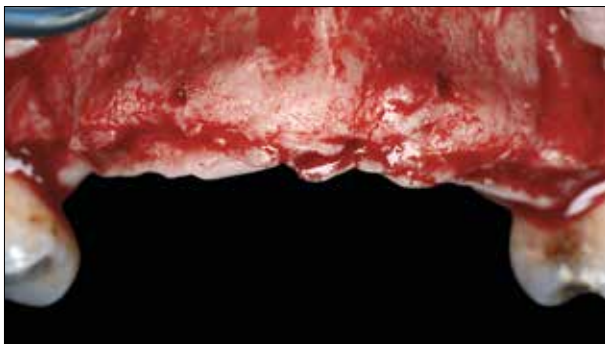


Fig 18 Flap elevation.

Computer-guided implant surgery

After twelve weeks of soft-tissue healing following the extractions (delayed implant placement protocol), the implants were placed with simultaneous contour augmentation using guided bone regeneration (GBR) based on the prosthetically driven digital planning.

As suggested by Gallucci and coworkers (2008), a segmented prosthetic design was selected for this case, with three separate bridges supported on implants (16–14, 13–11–21–23, 24–26).

Regarding implant placement at site 26, the patient was given a detailed explanation of the risks and benefits of sinus floor elevation versus a tilted implant. The patient chose the less invasive circumnavigation of the sinus by a tilted implant 26.

An initial hybrid surgical guide was supported by the palatal mucosa and by teeth 16, 17, 26, and 27. The stability and reproducibility of the position were checked (Figs 15 and 16). A palatal crestal incision was accompanied by flap elevation on the buccal side only, to allow for palatal seating. To improve the retention and stability of the guide during implant preparation, two stabilizing screws served as anchors at sites 12 and 22 (Figs 17 to 19).

Implant osteotomies were performed following the surgical protocol exported from the software (CoDiagnostiX) and as recommended by the implant manufacturer for computer-guided surgery:

1. Milling cutter (Fig 20)
2. Successive guided drills matching the corresponding guide-sleeve handles of the corresponding diameter (Fig 21)
3. Guided profile drills

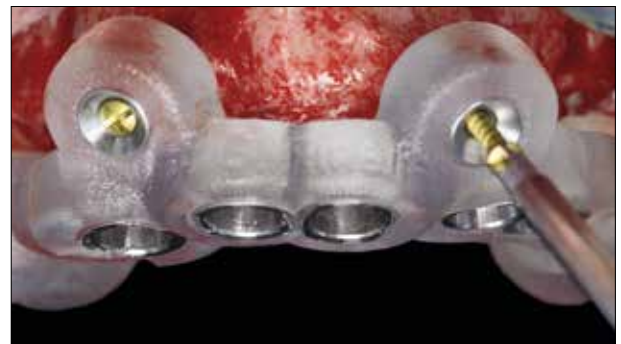

Fig 19 Insertion of a stabilizing screw before drilling through the guide.

Eight implants (Institut Straumann AG) (Table 1) with specific guided transfer abutments were placed under full surgical guidance, ensuring control of the axial position of the implant and its insertion depth (Figs 22 and 23).

Following the placement of the six anterior implants, teeth 16 and 25 were extracted and a second surgical template was utilized immediately to place implants into the interseptal bone of the sockets using a guided sequence similar to the one already described (Fig 24).

As expected from 3D planning, guided bone regeneration (GBR) using bone substitute with a low substitution rate (Cerabone; Botiss, Berlin, Germany) was required to increase the bone support on the buccal aspect of the anterior implants and to fill in the defects in the fresh extraction sockets. The grafts were covered with a non-crosslinked porcine resorbable collagen membrane (Jason membrane; Botiss) as a temporary barrier (Fig 25) during initial bone healing, in accordance with the principles of guided bone regeneration.

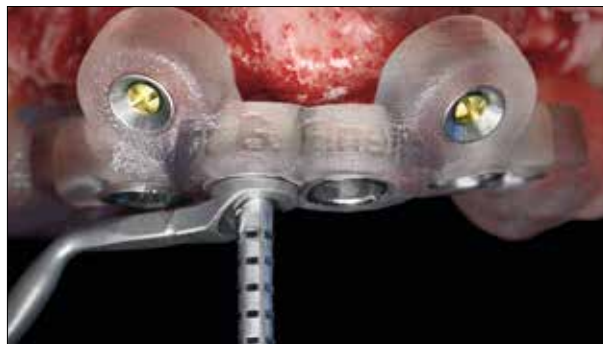


Fig 20 The first rotary instrument used for computer-guided surgery is the milling cutter (Institut Straumann AG).



Fig 21 Implementation of the drilling sequence using surgical drills and a matching handle set.

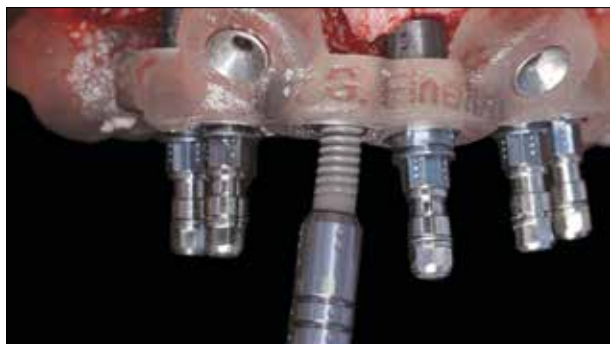

Fig 22 Guided insertion of the implant through the guide sleeves.

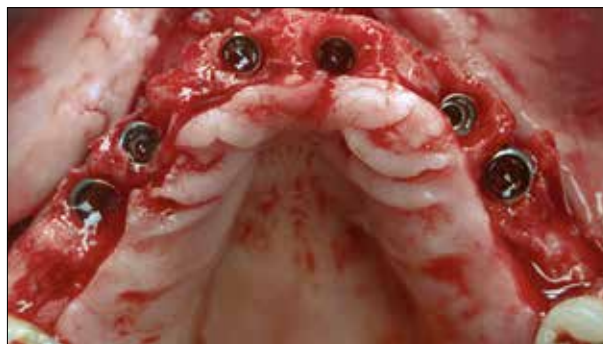

Fig 23 Six anterior bone-level implants in place (central incisors, canines, first premolars).

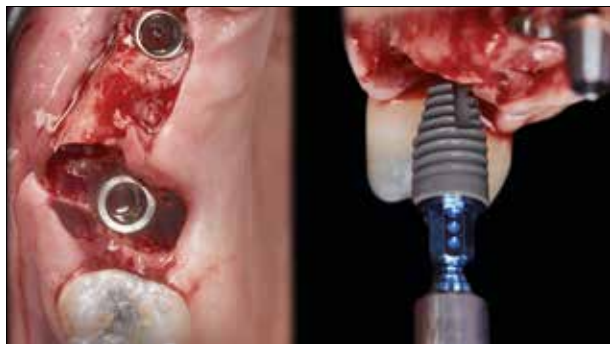

Fig 24 Immediate implant placement after the extraction of teeth 16 and 26.

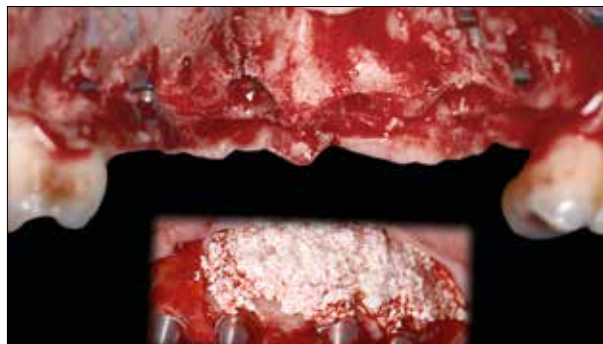


Fig 25 GBR procedure using a particulate xenograft bone substitute and a resorbable membrane.

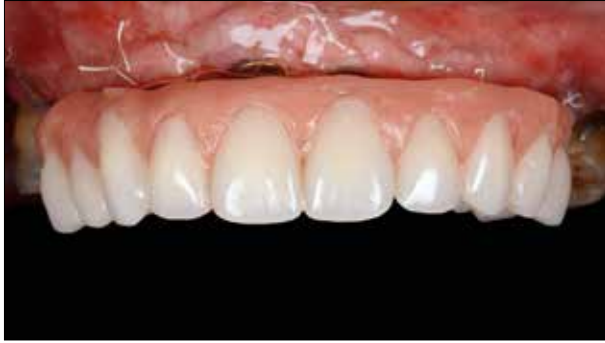

Fig 26 Interim removable prosthesis used during osseointegration.

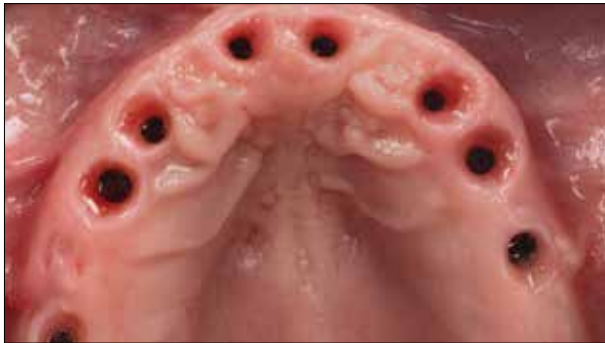

Fig 27 Clinical situation at eight weeks.

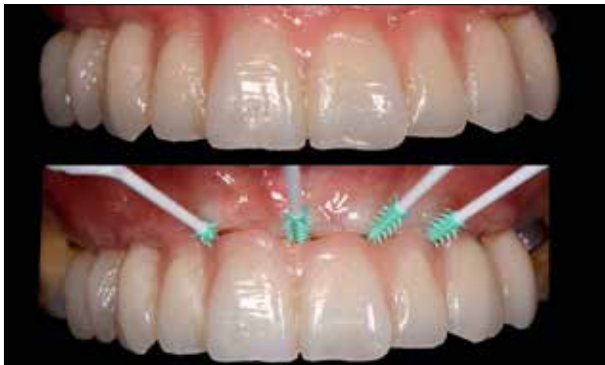

Fig 28 Screw-retained provisional: One-piece full-arch fixed restoration, designed with adequate access for plaque control.

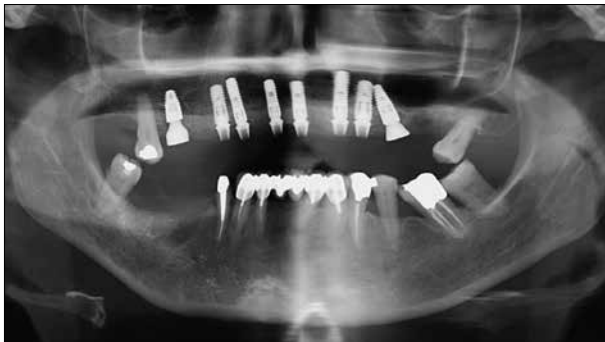

Fig 29 Panoramic radiograph after implant placement.

Table 1 List of implants placed

Site	Diameter (mm)	Length (mm)	Type	Surface
16	4.8	8	Regular CrossFit/ Bone Level Tapered	SLActive
14	4.1	10	Regular CrossFit/ Bone Level	SLActive
13	3.3	12	Narrow CrossFit/ Bone Level	SLActive
11	3.3	10	Narrow CrossFit/ Bone Level	SLActive
21	3.3	10	Narrow CrossFit/ Bone Level	SLActive
23	3.3	12	Narrow CrossFit/ Bone Level	SLActive
24	4.1	10	Regular CrossFit/ Bone Level	SLActive
26	4.1	10	Regular CrossFit/ Bone Level Tapered	SLActive
45	3.3	8	Regular Neck/ Standard Plus	SLActive
46	4.1	8	Regular Neck/ Standard Plus	SLActive

The flap was advanced using periosteal releasing incisions and the wound was closed with non-resorbable 5-0 suture material (Gore-Tex suture; Gore Medical, Flagstaff, AZ, USA). Teeth 17 and 27 were not extracted at the time, for the following reasons:

- To provide stable tooth support for the surgical guides
- To maintain the vertical dimension of occlusion (VDO) during the entire treatment up to the delivery of the final prosthesis)
- To help stabilize the provisional removable partial denture during implant osseointegration (six weeks) (Fig 26)

Provisionalization

Eight weeks postoperatively, the soft-tissue situation was healthy, and the contour of the of the arch was favorable (Fig 27). A conventional closed-tray impression was taken and a one-piece CAD/CAM (PMMA) screw-retained fixed provisional restoration was made in the laboratory following the initial diagnostic set-up (from the Digital Smile Design) (Figs 28 and 29).

Definitive rehabilitation

After a complication-free temporary phase, the final rehabilitation was planned to include three segmented bridges to allow for easier revision in case of technical complications, to offer improved options for cleaning, and to simplify laboratory procedures.

To minimize the distortion of the full-arch implant-level impression, a conventional open tray technique was performed using a polyvinyl siloxane (PVS) impression material, with the impression copings splinted together intraorally with rigid resin material (DuraLay; Reliance, Alsip, IL, USA) (Fig 30). A facebow recording was made at the same visit (Fig 31). The intermaxillary relationship was recorded using an implant-supported maxillary resin-based rim (DuraLay; Reliance) on which bite-registration material was positioned. The VDO was controlled by teeth 17, 27, which had been retained for this purpose.

In order to aid the CAD/CAM design of the definitive prosthetic framework, a polyvinyl siloxane impression of the provisional restoration was taken. A conventional stone master model with implant analogs was then poured from the impressions.

To validate the precision and trueness of the master cast and ensure a predictable passive fit of the future restoration, three stone verification indices (corresponding to the segmented design selected) were inserted into the implant connections. No fractures of these indices occurred, confirming a satisfactory passive fit (Fig 32).

Both models were mounted in an articulator (Artex; Amann Girrbach, Koblach, Austria) in the correct intermaxillary relationship and digitized (Dental Wings) (Fig 33). Prior to scanning the models, digital scanbodies were inserted into each implant analog. The mounted maxillary and mandibular casts and the model of the provisional restoration were sent to an external milling facility (Createch Medical, Pabellón, Spain) to assist in the digital workflow of model scanning and the design and milling of a titanium framework.

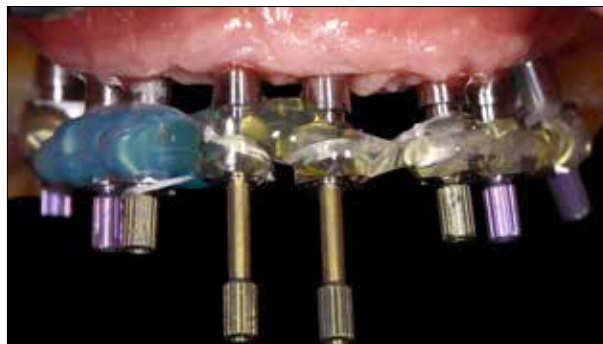

Fig 30 Final conventional open tray impression with splinted impression posts.

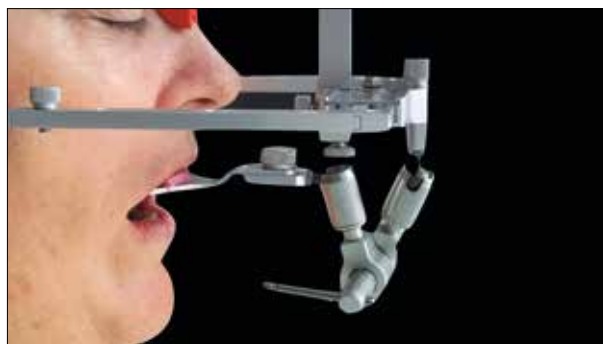


Fig 31 Facebow registration.

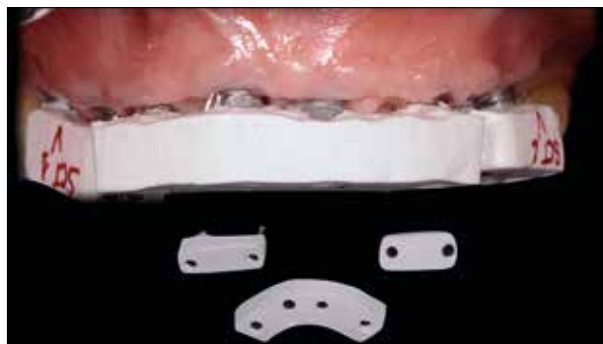

Fig 32 Validation of the accuracy of the working model with segmented stone indices.

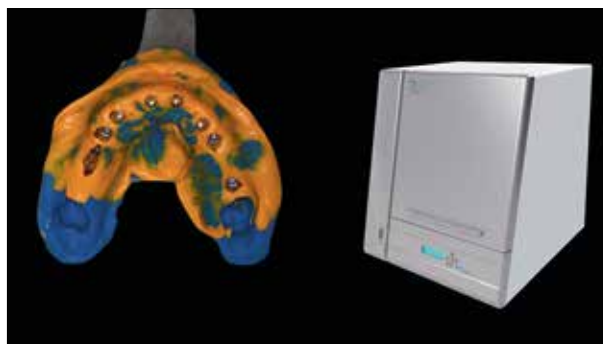


Fig 33 The impression is poured out and the model scanned.



Fig 34 Design of three reduced titanium frameworks.

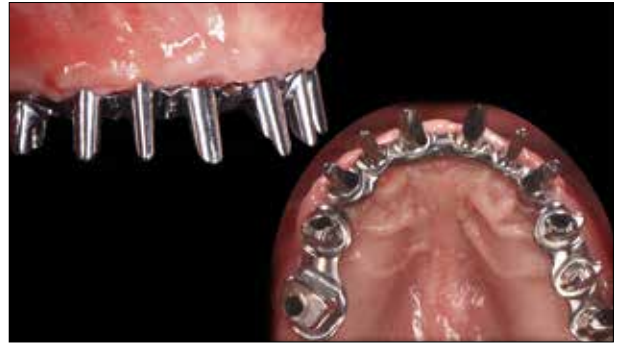

Fig 35 Framework try-in.

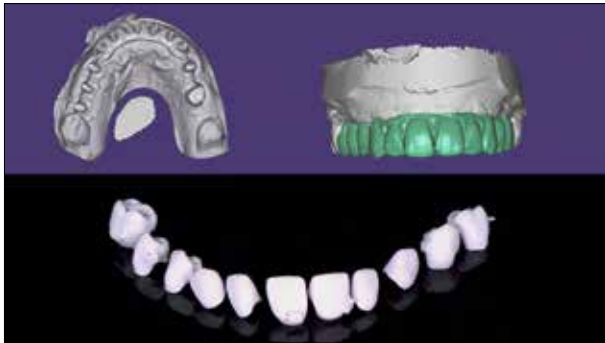

Fig 36 Design and fabrication of twelve individually milled monolithic CAD/CAM ceramic crowns (e.max CAD; Ivoclar Vivadent; lithium disilicate).

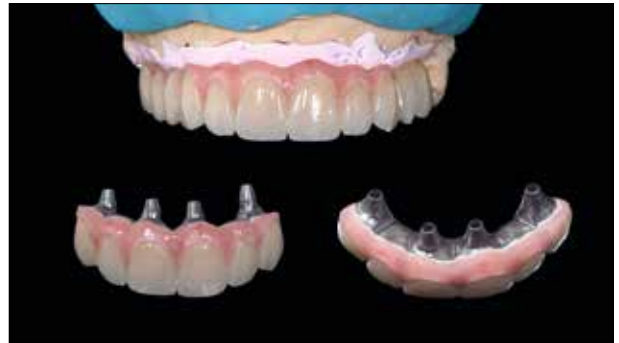

Fig 37 Final bridge ready for delivery after staining and cementation of the individual crowns onto the framework.

The final titanium framework was carried designed by the laboratory (Laboratoire Nouvelle Technologie, Paris, France) in collaboration with the milling company (Createch Medical). Three titanium frameworks were constructed using non-indexed implant connections. The gingival framework was veneered with gingiva-colored ceramics. Individual monolithic crowns were constructed and cemented onto the framework (Figs 34 and 35). A passive fit with adequate occlusal space was confirmed at the clinical try-in.

Gingiva-colored ceramic material was layered and sintered onto the titanium framework at the laboratory. Sixteen custom CAD/CAM crowns were designed (Dental Wings) and milled in lithium disilicate (IPS e.max CAD; Ivoclar Vivadent). After staining and sintering, the crowns were individually cemented (glass-ionomer cement) onto the framework. Crowns located at implant positions were designed to allow screw access (Figs 36 and 37).

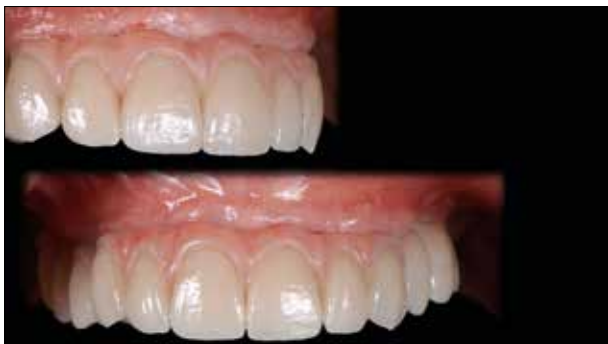

Fig 38 Final delivery of the bridge.

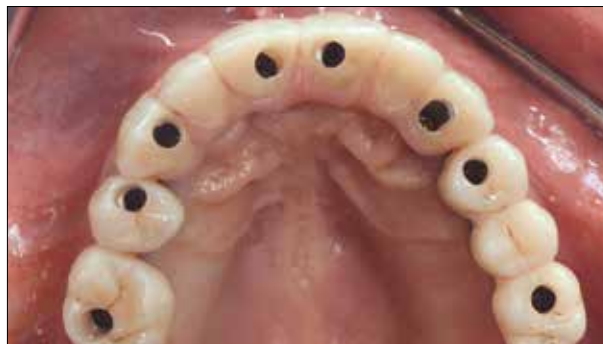

Fig 39 Occlusal view showing the screw-retained design.

The three segmented bridges (16–14, 13–11–21–23, 24–26) were screwed onto the respective implants at a torque of 35 Ncm. The screw access holes were sealed with PTFE rubber and composite (Gænial A02; GC, Tokyo, Japan) (Figs 38 and 39). At the 18-month follow-up, the peri-implant soft tissues showed no signs of inflammation and no significant bone resorption, and panoramic radiographs confirmed the correct insertion of the prosthesis. The patient felt comfortable and was satisfied with the esthetics, phonetics, and function of the restoration (Figs 40 to 42).

The lower arch was reconstructed using conventional restorative techniques, with a combination of conventional ceramic crowns and bridge restorations on the retained teeth (e.max Press; Ivoclar) and implant-supported crowns bonded onto Variobase abutments (Institut Straumann AG).

Follow-up visits including professional oral hygiene were scheduled every six months to ensure proper maintenance and check the efficacy of the patient's own oral hygiene.

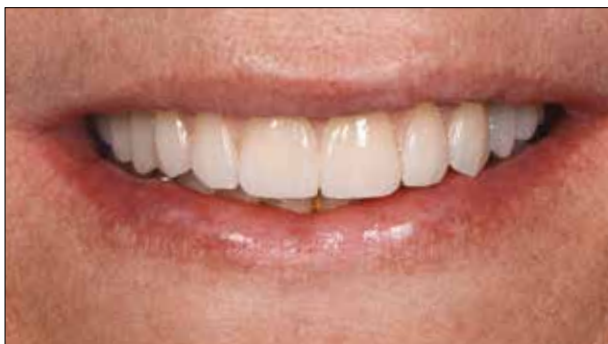

Fig 40 Patient smile after delivery.

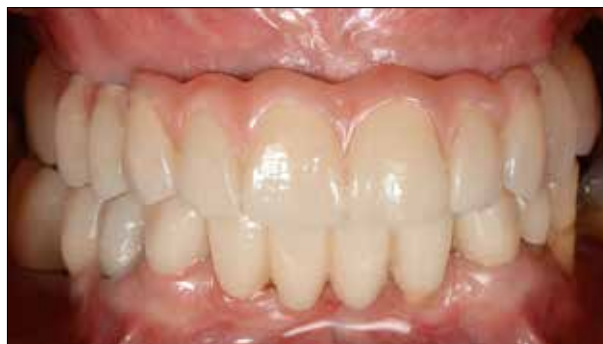

Fig 41 Intraoral view at the 18-month follow-up, including all definitive restorations.

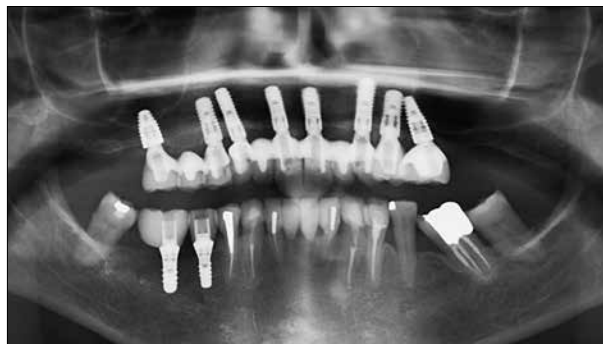

Fig 42 Panoramic X-ray at the 18-month follow-up.